

# Nursing Priorities in Caring for Patients with Intracerebral Hemorrhage

Mary Presciutti

**Abstract:** Patients afflicted with intracerebral hemorrhage (ICH) experience potentially devastating neurological sequelae; current therapy for ICH remains supportive. However, hemostatic therapy with recombinant activated factor VIIa holds promise for decreasing the morbidity and mortality of patients following an ICH. Nurses who are the responsible clinicians at the bedside often find it challenging to care for these patients. This article discusses the priorities that nurses need to determine as they balance the overall needs of the patient, incorporating recombinant activated factor VIIa as a new treatment for ICH.

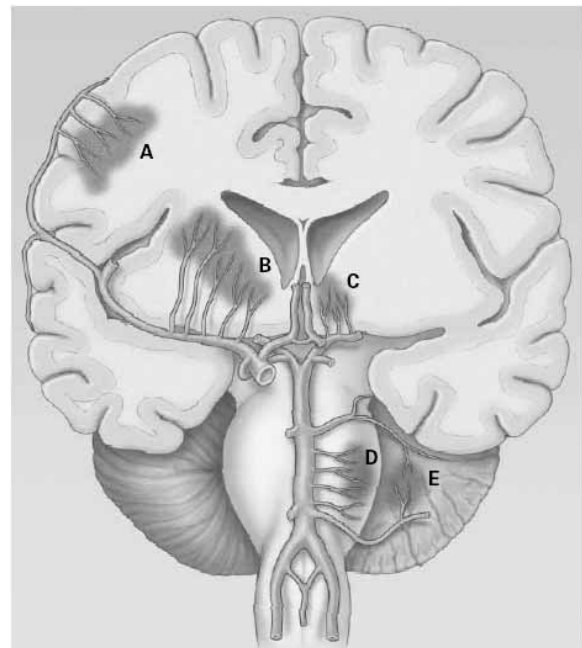
Intracerebral hemorrhage (ICH), defined as the bleeding of small vessels in the brain parenchyma, is the most unfavorable type of stroke. It has a significant incidence of morbidity and mortality (Broderick et al., 1999; Fewel, Thompson, & Hoff, 2003; Qureshi et al., 2001). ICH afflicts 37,000–52,000 people in the United States annually (Qureshi et al.), frequently in elderly or middle-aged people, African Americans, Asians (particularly Japanese), and those with hypertension (Broderick et al., 1999; Qureshi et al.). Nurses in emergency room or intensive care settings often face the critical task of prioritizing aspects of care for these patients. Their focus is on early recognition of complications and institution of life-saving interventions for ICH. A promising new treatment has emerged: the use of recombinant activated factor VIIa (VIIa) as an adjunct to widely accepted traditional medical and surgical management algorithms. Since nurses are the primary caregivers of patients with ICH, they need to be aware of the use of VIIa.

The focus of this article is on important nursing priorities in the critical phase following ICH and implementation of a new treatment option.

## Risk Factors

Uncontrolled hypertension is the primary and most easily modifiable risk factor for ICH (Mayer & Rincon, 2005). Other risk factors include advancing age and cerebral amyloid angiopathy (Fewel et al., 2003; Qureshi et al., 2001). Secondary causes of ICH include

neoplasm; hypocholesterolemia (Badjatia & Rosand, 2005); coagulation disorders; use of illicit drugs or anticoagulants; excessive alcohol intake; and vascular anomalies such as arteriovenous malformations and aneurysms (Broderick et al., 1999; Quinones-Hinojosa, Gulati, Singh, & Lawton, 2003; Qureshi et al., 2001).



**Fig 1.** Common sites and sources of intracerebral hemorrhage. Intracerebral hemorrhages most commonly involve (A) cerebral lobes, originating from penetrating cortical branches of the anterior, middle, or posterior cerebral arteries; (B) basal ganglia, originating from ascending lenticulostriate branches of the middle cerebral artery; (C) the thalamus, originating from ascending thalamogeniculate branches of the posterior cerebral artery; (D) the pons, originating from paramedian branches of the basilar artery; (E) the cerebellum, originating from penetrating branches of the posterior, inferior, anterior inferior, or superior cerebellar arteries.

From "Spontaneous Intracerebral Hemorrhage," by A. I. Qureshi, S. Tuhrim, J. P. Broderick, H. H. Batjer, H. Hondo, and D. Hanley, 2001, *New England Journal of Medicine*, 344, 1450–1460. Copyright 2001 by Massachusetts Medical Society. Reprinted with permission.

Questions or comments about this article may be directed to Mary Presciutti, RN CCRN CNRN, at lanipres@yahoo.com. She is a staff nurse in the Neuroscience Intensive Care Unit at New York Presbyterian Hospital, New York, NY.

Copyright © 2006 American Association of Neuroscience Nurses 0047-2606/06/3804(Suppl.)/00296\$5.00

## Pathophysiology

When ICH occurs, small, deep-penetrating arteries rupture, causing bleeding into the brain parenchyma. Bleeding can occur in the cerebral hemispheres, basal ganglia, brainstem, cerebellum, or the ventricles, causing initial tissue injury (Fewel et al., 2003; Qureshi et al., 2001). Fig. 1 shows the common sites and sources of ICH. The hematoma also has the potential to disturb normal intracranial dynamics, causing a sudden rise in intracranial pressures, tissue compression, displacement, and herniation from mass effect (Fewel et al. Qureshi et al.).

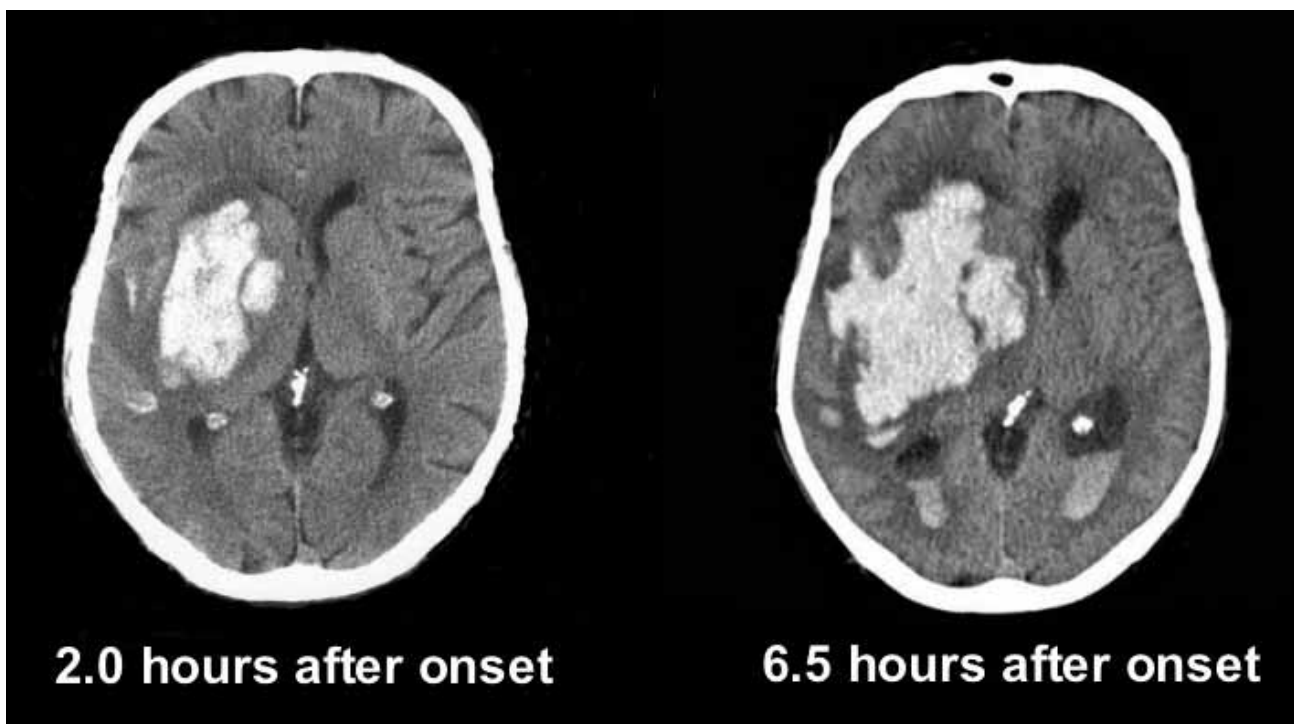
Recent studies have shown that early hematoma growth (expansion) and perihematomal injury are associated with neurologic deterioration (Mayer, 2003; Mayer & Rincon, 2005). Early hematoma expansion can be caused by continued bleeding, blood-brain barrier breakdown, or formation of a local coagulopathic state (Badjatia & Rosand, 2005; Mayer & Rincon). This phenomenon has been observed even in noncoagulopathic patients (Mayer et al., 2005). According to Qureshi et al. (2001), acute neurological deterioration can usually be attributed to an increase in the size of the hematoma or obstructive hydrocephalus, whereas delayed worsening is usually due to the formation of edema.

Secondary brain injury is believed to be mediated by the presence of perihematomal blood and plasma (Badjatia & Rosand, 2005; Fewel et al., 2003; Mayer, 2003; Mayer & Rincon, 2005; Qureshi et al., 2001). Patients with

ICH had high levels of excitatory and inflammatory molecules such as glutamate, interleukin-6, and tumor necrosis alpha. These findings suggested that inflammation and excitotoxicity could play a role in secondary brain injury (Castillo et al., 2002; Mayer & Rincon; Rincon & Mayer, 2004). Another theory suggests that plasma containing thrombin and other coagulation products leaks into the surrounding brain tissue. Studies have suggest that thrombin, matrix-metalloproteases, white blood cell mobilization, and disruption in the permeability of blood brain barrier are all contributing factors that lead to the development of perihematomal injury (Fewel et al.; Mayer; Mayer & Rincon). In a study by Leira et al. (2004), temperatures  $>37.5^{\circ}\text{C}$  and elevated neutrophil counts and fibrinogen levels were found in patients following ICH. Again, these inflammatory markers may be associated with secondary brain injury.

## Clinical Manifestation

An intraparenchymal hematoma produces sudden neurological symptoms that depend on the size and location of the hemorrhage. Hematoma growth, intraventricular extension, and high systolic blood pressures have all been associated with early neurological deterioration (Leira et al., 2004). Slurred speech, aphasia, hemiparesis or hemiplegia, seizures, and coma are more common with supratentorial hemorrhages. Ataxia, cranial nerve dysfunction, nystagmus and coma are related to cerebellar or infratentorial ICH (Broderick et



**Fig 2.** Early hematoma growth in a 48-year-old chronically hypertensive woman. From "Treatment of Intracranial Hemorrhage," by S. Mayer and F. Rincon, 2005, *Lancet Neurology*, 4, pp. 662–672. Copyright 2005 by Elsevier. Reprinted with permission.

al., 1999; Fewel et al., 2003; Qureshi et al., 2001). Associated clinical manifestations may vary from headache to severe hypertension, nausea, vomiting, and coma (Mayer & Rincon, 2005).

## Diagnosis

Intracerebral hemorrhage is a medical emergency (Broderick et al., 1999). Initial diagnosis is achieved by using an emergent brain computed tomography (CT) scan upon presentation. A CT scan can distinguish between hemorrhagic and ischemic strokes (Broderick et al., 1999; Fewel et al., 2003; Qureshi et al. 2001). Fig. 2 shows a CT scan comparing the brain at 2 and 6.5 hours after ICH onset. Other neuroimaging studies include magnetic resonance imaging (MRI) and cerebral angiography, which may be performed urgently, depending on the patient's clinical status. MRI can detect past hemorrhages, amyloid angiopathy, and neoplasm (Badjatia & Rosand, 2005; Mayer & Rincon 2005). Cerebral angiography can be useful in determining whether a vascular malformation or an aneurysm is the cause of ICH (Broderick et al.; Fewel et al.; Qureshi et al.).

## Initial Management

Emergency medical management focuses on the immediate threat to life. Initial resuscitation measures and life-saving interventions such as airway protection, intubation, and proper ventilatory support, as well as such routine actions as obtaining vital signs, establishing intravenous access for medications, and performing brief neurological assessment are performed in parallel (Badjatia & Rosand, 2005; Broderick et al., 1999; Pouratian, Kassell, & Dumont, 2003). The Glasgow Coma Scale is often used for neurological assessment (Badjatia & Rosand). Patients who have a decreased level of consciousness or an unprotected airway must be intubated and supported by a ventilator to avoid aspiration, hypoxemia or hypercapnia (Mayer & Rincon, 2005). Increased intracranial pressure (ICP) must be relieved immediately.

Nurses can assist neurosurgeons with the emergent insertion of an external ventricular drain, which is a life-saving measure for patients with an ICH that extends into the ventricles with concomitant hydrocephalus (Broderick et al., 1999). Other therapies used to treat elevated ICP include head elevation, cerebral perfusion pressure optimization, hyperosmolar therapy, sedation, and fever control (Badjatia & Rosand, 2005; Broderick et al.; Mayer & Rincon, 2005; Pouratian et al., 2003). Cardiovascular stabilization is also a priority. Careful attention is paid to the patient's blood pressure in conjunction with the cerebral perfusion pressure (Broderick et al., 1999). In a small retrospective study, blood pressures >160 mm Hg were correlated with an interval increase in the size of the hematoma; a lower target blood pressure (i.e., <150

mm Hg) might be beneficial in arresting this process (Ohwaki, Nagashima, Hirata, Nakagomi, & Tamura, 2004). Current guidelines deem the treatment of hypertension with an appropriate antihypertensive, such as labetalol and nicardipene infusions, as the standard of care. Mean arterial pressure should be <130 mm Hg in patients with a history of hypertension. For patients who are hypotensive, vasopressors, such as phenylephrine, dopamine, and norepinephrine are used to keep systolic blood pressure >90 mm Hg and cerebral perfusion pressure >70mm Hg, (Broderick et al.).

Data evaluated on admission identify any comorbid medical conditions (Badjatia & Rosand, 2005). These data include electrocardiogram, patient's weight, serum chemistries, complete blood count, coagulation profile, and urine toxicology. The international normalized ratio value, if elevated, is corrected by administering blood products such as fresh frozen plasma, platelets, and packed red blood cells, along with vitamin K (Broderick et al., 1999; Quinones-Hinojosa et al., 2003).

For a patient with a cerebellar ICH larger than 3 cm who is deteriorating or has brainstem compression, surgical clot evacuation can be a life-saving treatment. For a supratentorial hemorrhage, clot evacuation is recommended in young patients with a moderate or large lobar hemorrhage and in patients with hemorrhage associated with a structural lesion, such as aneurysm or arteriovenous malfunction. (Broderick et al., 1999).

## New Treatment Option

Expansion of the hematoma is one of the factors that determine the outcome for patients with ICH (Mayer, 2003). Originally, it was hypothesized that arresting hematoma expansion might improve outcome in patients with ICH (Mayer). The administration of VIIa to patients with ICH may promote coagulation at the site of hemorrhage, thus preventing clot expansion without activating the systemic coagulation cascade (Fewel & Park, 2004; Mayer et al., 2005). Recombinant activated factor VIIa has been approved by the Food and Drug Administration and is widely used for treatment of hemophiliacs who have inhibitors to factors VIII and IX. Factor VIIa promotes hemostasis by forming a complex with tissue factor pathway, which is released following endothelial vascular injury. Activating the tissue factor pathway stimulates other clotting factors, which eventually generate thrombin, forming a clot.

In a phase IIIb randomized, double-blind, placebo-controlled trial of 400 patients, VIIa was administered according to the patient's weight. Doses of 40 mcg/kg, 80 mcg/kg, and 160 mcg/kg were given as a single intravenous injection over 1–2 minutes within the first 4 hours of hemorrhage. Treatment with VIIa decreased the size of the hematoma. Thromboembolic adverse events occurred in 7% of treated patients, compared to 2% in

the placebo group. A phase III confirmatory trial of VIIa is currently under way (Mayer et al., 2005).

## Nursing Responsibilities

Nursing care for patients with ICH is as critical as medical and surgical treatments. Nursing responsibilities center on vigilant monitoring for physiological changes (Hickey, 2003). Collaboration with the health-care team is necessary. Despite advances in technology, frequent and careful neurological examination of the patient remains critical. Any significant change in the patient's neurological exam (e.g., decline, worsening deficit in mental status) requires an emergent CT scan to reassess size of the hemorrhage. In patients with elevated ICP, therapies to reduce ICP would be instituted, as previously discussed. Adequacy of oxygenation is monitored; oxygen saturation, arterial blood gases, and end-tidal CO<sub>2</sub> levels are measured and supplemental oxygen supplied (Hickey).

Other nursing responsibilities include optimizing blood pressure parameters, which means careful titration of various vasoactive drugs (Hickey, 2003). Because fever is a well-known independent predictor of outcome in neurologically injured patients, cultures must be obtained and treatment started immediately with such cooling mechanisms as cold air-circulating blankets or the newer type of cooling catheters or blankets (Mayer, Commichau et al., 2001; Mayer, Kowalski et al., 2004). Blood glucose must be tightly controlled. If used, an insulin drip to maintain a normoglycemic state must be carefully titrated. In prospective randomized trials, frequent blood glucose monitoring, together with insulin therapy, led to decreased morbidity and mortality in critically ill patients (Badjatia & Rosand, 2005; Byrum, 2004; Pouratian et al., 2003; Van Den Berghe et al., 2001). Patients receiving hyperosmolar therapy with either mannitol or hypertonic saline must have their electrolytes monitored frequently (at least every 6 hours) to maintain adequate electrolyte balance and prevent complications. Fluid management is guided by central venous pressures or pulmonary artery pressures during hyperosmolar therapy (Bhardwaj & Ulatowski, 1999; Mayer & Rincon, 2005).

Convulsive and nonconvulsive seizures occur in 28% of patients following ICH (Vespa et al., 2003). Nursing responsibilities center on monitoring for clinical seizure activity in patients with or without continuous electroencephalography recording (Mayer & Rincon, 2005) and administering and monitoring of antiepileptic drugs and levels, as ordered.

Nurses are involved in the assessment of discharge needs of the patient, which is initiated on admission. Early needs assessment helps facilitate initial rehabilitation planning with the interdisciplinary team. Other basic nursing responsibilities require the prevention of pressure ulcers, nosocomial infections, and deep vein thrombosis and collaboration with the nutritionist while monitoring

the patient's nutritional intake. Another important aspect of a nurse's responsibility is to attend to the patient's and family's psychosocial and spiritual needs. The latter may be achieved not only by making the appropriate social worker and religious care referrals but also by spending time with the patient and family, comforting them, keeping them informed of ongoing therapies, anticipating their needs, or just being present (Benner, 1984). Caring actions are one of the nurse's best interventions.

## Summary

The evolution in the understanding of the pathophysiology of ICH is exciting and could lead to new treatments in the future. Recombinant activated factor VIIa has recently been determined to help arrest hematoma expansion—a strong determinant in patient outcomes. Any cure or palliative treatment that arrests hematoma expansion would advance the treatment of ICH. Hemostatic therapy with VIIa holds the potential of reducing morbidity and mortality in these patients. At the same time, these patients continue to require complex life-supporting interventions in which nurses play a critical role. Knowledgeable and skilled nurses have the ability to discern and communicate subtle changes in the patient's condition to prevent secondary injury and complications.

## References

- Badjatia, N., & Rosand, J. (2005). Intracerebral hemorrhage. *Neurologist*, *11*, 311–324.
- Benner, P. (1984). *From novice to expert*. Menlo Park, CA: Addison-Wesley.
- Bhardwaj, A., & Ulatowski, J. (1999). Hypertonic saline solutions. *Current Treatment Options in Neurology*, *1*, 179–187.
- Broderick, J. P., Harold, A. P., Barsan, W., Feinberg, W., Feldmann, E., Grotta, J., et al. (1999). Guidelines for the management of spontaneous intracerebral hemorrhage: A statement for healthcare professionals from a special writing group of the Stroke Council, American Heart Association. *Stroke*, *30*, 905–915.
- Byrum, D. (2004). Ask the experts. *Critical Care Nurse*, *24*(2), 86–90.
- Castillo, J., Dávalos, A., Álvarez-Sabin, J., Pumar, J. M., Leira, R., Silva, Y., et al. (2002). Molecular signatures of brain injury after intracerebral hemorrhage. *Neurology*, *58*, 624–629.
- Fewel, M. E., & Park, P. (2004). The emerging role of recombinant-activated factor VII in neurocritical care. *Neurocritical Care*, *1*, 19–33.
- Fewel, M. E., Thompson, B. G., Jr., & Hoff, J. T. (2003). Spontaneous intracerebral hemorrhage: A review. *Neurosurgical Focus*, *15*(4), 1–13.
- Hickey, J. (2003). *The clinical practice of neurological and neurosurgical nursing* (5th ed.). Philadelphia: Lippincott Williams & Wilkins.
- Leira, R., Dávalos, A., Silva, Y., Gil-Peralta, A., Tejada, J., Garcia, M., et al. (2004). Early neurologic deterioration in intracerebral hemorrhage. *Neurology*, *63*, 461–467.
- Mayer, S. A. (2003). Ultra-early hemostatic therapy for intracerebral hemorrhage. *Stroke*, *34*, 224–229.
- Mayer, S. A., Brun, N. C., Broderick, J., Davis, S., Diringer, M. N., Skolnick, B. E., et al. (2005). Safety and feasibility of recombinant factor VIIa for acute intracerebral hemorrhage. *Stroke*, *36*, 74–79.

*continued on page 315*

# Nursing Priorities in Caring for Patients with Intracerebral Hemorrhage

continued from page 299

- Mayer, S. A., Kowalski, R. G., Presciutti, M., Opstakovich, N. D., McGann, E., Fitzsimmon, B., et al. (2004). Clinical trial of a novel surface cooling system for fever control in neurocritical care patients. *Critical Care Medicine*, *32*, 2508–2516.
- Mayer, S., & Rincon, F. (2005). Treatment of intracerebral hemorrhage. *Lancet Neurology*, *4*, 662–672.
- Ohwaki, K., Nagashima, H., Hirata, M., Nakagomi, T., & Tamura, A. (2004). Blood pressure management in acute intracerebral hemorrhage: Relationship between elevated blood pressure and hematoma enlargement. *Stroke*, *35*, 1364–1367.
- Pouratian, N., Kassell, N. F., & Dumont, A. S. (2003). Update on management of intracerebral hemorrhage. *Neurosurgery Focus*, *15*(4), 1–6.
- Quinones-Hinojosa, A., Gulati, M., Singh, V., & Lawton, M. (2003). Spontaneous intracerebral hemorrhage due to coagulation disorders. *Neurosurgical Focus*, *15*(4), 1–15.
- Qureshi, A. I., Tuhim, S., Broderick, J. P., Batjer, H. H., Hondo, H., & Hanley, D. (2001). Spontaneous intracerebral hemorrhage. *New England Journal of Medicine*, *344*, 1450–1460.
- Rincon, F., & Mayer, S. A. (2004). Novel therapies for intracerebral hemorrhage. *Current Opinions in Critical Care*, *10*, 94–100.
- Van Den Berghe, G., Wouters, P., Weekers, F., Verwaest, C., Bruyninckx, F., Schetz, M., et al. (2001). Intensive insulin therapy in critically ill patients. *New England Journal of Medicine*, *345*, 1359–1367.
- Vespa, P. M., O'Phelan, K., Shah, M., Mirabelli, J., Starkman, S., Kidwell, C., et al. (2003). Acute seizures after intracerebral hemorrhage: A factor in progressive midline shift and outcome. *Neurology*, *60*, 1441–1446.

## Continuing Education Credit

*Journal of Neuroscience Nursing* is pleased to offer the opportunity to earn neuroscience nursing contact hours for this article online. Go to [www.aann.org](http://www.aann.org), and select "Continuing Education." There you can read the article again or go directly to the posttest assessment. The cost is \$15 for each article. You will be asked for a credit card or online payment service number.

The posttest consists of 10 questions based on the article, plus several assessment questions (e.g., How long did it take you to read the article and complete the posttest?). A passing score of 80% (8 of 10 questions correct) on the posttest and completion of the assessment questions yields 1 nursing contact hour for each article.

The American Association of Neuroscience Nurses is accredited as a provider of continuing nursing education by the American Nurses Credentialing Center's Commission on Accreditation.