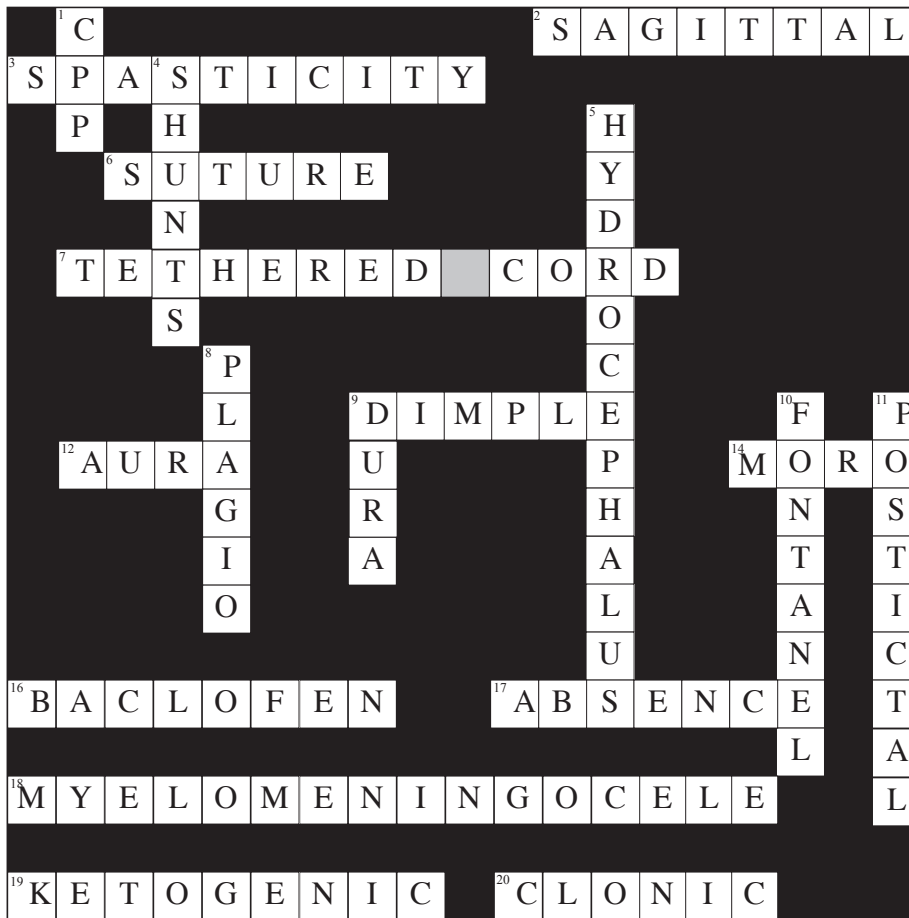


A Pediatric Puzzle

Judie Holleman, Patti Ogden



Across

2. Suture most commonly prematurely closed
3. Syndrome of uncontrolled skeletal muscle contractions
6. Causes craniosynostosis if prematurely closed
7. Fastening of filum terminale to spinal canal
9. A small hollow, when present on the back, could signal tethered cord
12. Sensations experienced before seizure or migraine headache
14. Startle reflex that disappears by 3–4 months
16. An antispasticity agent
17. Previously known as petit mal seizure
18. Neural tube defect with protrusion of meninges and abnormal cord
19. Diet used to treat intractable epilepsy
20. Jerking movements in a seizure episode

Down

1. MAP-ICP
4. Devices to redirect CSF
5. Abnormal accumulation of CSF
8. Type of cephalo with occipital flatness
9. Tough layer of tissue over the brain
10. Opening in the skull bones that eventually closes
11. Period of confusion after a seizure

Judie Holleman, MSN RN PCCNP, and Patti Ogden, MSN RN, are from the University of Chicago Comer Children's Hospital in Chicago.

This is the solution to "A Pediatric Puzzle," which appeared in the June 2006 issue of Journal of Neuroscience Nursing (page 200).