

# Care of the Patient Undergoing Intracranial Pressure Monitoring/ External Ventricular Drainage or Lumbar Drainage

AANN Clinical Practice Guideline Series



This publication was made possible by an educational grant from Codman and Shurtleff, a Johnson & Johnson Company.



**American Association of Neuroscience Nurses**  
4700 W. Lake Avenue  
Glenview, IL 60025-1485  
888.557.2266  
International phone 847.375.4733  
Fax 847.375.6430  
info@aann.org • www.AANN.org

**AANN Clinical Practice Guideline Series Editor**

Hilaire J. Thompson, PhD RN CNRN FAAN

**Content Authors**

Tess Slazinski, MN RN CNRN CCRN, Chair

Tracey A. Anderson, MSN RN CNRN FNP-BC ACNP

Elizabeth Cattell, MN CNRN ACNP-BC

Janice E. Eigsti, MSN RN CNRN CCRN

Susan Heimsoth, BSN RN

Judie Holleman, MSN RN

Amanda Johnson, MSN RN CPNP

Mary L. King, MSN/Ed RN CNRN

Twyila Lay, MS RN ACNP ANP

Mary Presciutti, BSN RN CNRN CCRN

Robert S. Prior, RN CNRN

Brian A. Richlik, BSN RN CNRN CCRN

Shawn Schmelzer, BSN RN CCRN

Anna Ver Hage, BSN RN CNRN CCRN

Carol L. Wamboldt, MSN CRNP CNRN

Kelly White, BSN RN CNRN CCRN

Paula Zakrzewski, MSN RN CPNP-AC

**Content Reviewers**

Angela K. Aran, BSN RN CNRN CCRN

Julia Galletly, MS ACNP-BC CCRN

Norma McNair, PhD(c) RN

Kristina Nolte, RN CCRN CNRN ATCN

**AANN Clinical Practice Guideline Editorial Board**

Sheila Alexander, PhD RN

Patricia Blissitt, PhD RN APRN-BC CCRN CNRN CCNS  
CCM

Tess Slazinski, MSN RN CCRN CNRN

Patricia Zrelak, PhD CNA-BC CNRN

**AANN National Office**

Joan Kram

*Executive Director*

June M. Pinyo, MA

*Managing Editor*

Sonya L. Jones

*Senior Graphic Designer*

**Publisher's Note**

The authors, editors, and publisher of this document neither represent nor guarantee that the practices described herein will, if followed, ensure safe and effective patient care. The authors, editors, and publisher further assume no liability or responsibility in connection with any information or recommendations contained in this document. These recommendations reflect the American Association of Neuroscience Nurses' judgment regarding the state of general knowledge and practice in our field as of the date of publication and are subject to change based on the availability of new scientific information.

Copyright ©2011 by the American Association of Neuroscience Nurses. No part of this publication may be reproduced, photocopied, or republished in any form, print or electronic, in whole or in part, without written permission of the American Association of Neuroscience Nurses.

## Preface

To meet its members' needs for educational tools, the American Association of Neuroscience Nurses (AANN) has created a series of guidelines for patient care called the AANN Clinical Practice Guideline Series. Each guideline has been developed based on current literature and evidence-based practice. The purpose of this document is to assist registered nurses (RNs), patient care units, and institutions in providing safe and effective care to patients undergoing intracranial pressure (ICP) monitoring via an external ventricular drainage device (EVD) or those undergoing subarachnoid drainage of cerebrospinal fluid (CSF) with a lumbar drainage device (LDD). This guideline replaces two previous guidelines, *Care of the Patient with Intracranial Pressure Monitoring* and *Care of the Patient with a Lumbar Drain*. This new guideline, *Nursing Care Management of the Patient Undergoing Intracranial Pressure Monitoring/External Ventricular Drainage or Lumbar Drainage*, is based on current evidence and practice standards. For further information on management of the patient with elevated ICP, users should refer to specific patient population guidelines available at [www.aann.org/pubs/content/guidelines.html](http://www.aann.org/pubs/content/guidelines.html).

Neuroscience nursing care of the patient with an ICP monitoring device, EVD, or LDD is inherently complex. This complexity arises from the meticulous monitoring and multidimensional clinical decision making required for nurses to provide optimal care. Providing resources and recommendations for practice at the bedside should enable the nurse to make decisions that will optimize patient outcomes. This practice guideline is an essential resource

for neuroscience nurses responsible for the care of a patient whose clinical status requires such invasive monitoring and therapy. This guideline is not intended to replace formal learning, but rather to augment the knowledge base of clinicians and provide a readily available reference tool. This guide is limited to ICP monitoring via an EVD.

The RN is designated as qualified to provide care for the patient with an ICP monitoring device, EVD, or LDD following educational and clinical experience set by the institution's policies and procedures. The individual practice setting should have written policies and procedures specific to the type of device used. These policies and procedures should delineate who may perform specific practices. Practitioner delineation should be based on state nurse practice acts, regional and institutional norms, and the feasibility of maintaining competency for infrequently performed procedures. Evaluation of competency in the care of these patients should be established by the administrative authority of the institution. Frequency of evaluation should be based on the volume and risk of the practice, but a minimum of annual competency evaluation is recommended. To maintain a current knowledge base, ongoing participation in education on the management of patients undergoing subarachnoid drainage of CSF using an EVD or LDD is recommended at least once per year.

Neuroscience nursing and AANN are indebted to the volunteers who have devoted their time and expertise to this valuable resource, created for those who are committed to neuroscience patient care.

# Table of Contents

<b>I. Introduction</b> .....	<b>4</b>
A. Problem statement and guideline goal. ....	4
B. Assessment of scientific evidence .....	4
<b>II. Anatomy and physiology</b> .....	<b>4</b>
A. Brain .....	4
B. CSF and the ventricular system .....	4
C. Monro-Kellie hypothesis .....	5
<b>III. ICP monitoring and EVD</b> .....	<b>5</b>
<b>IV. Indications for EVD placement</b> .....	<b>6</b>
<b>V. ICP waveform analysis</b> .....	<b>6</b>
<b>VI. EVD equipment setup</b> .....	<b>8</b>
A. Equipment needed .....	8
B. Priming the EVD .....	8
C. Zeroing and calibration of the EVD .....	9
D. Obtaining ICP tracing .....	10
E. Draining CSF .....	10
<b>VII. Ventricular catheter insertion</b> .....	<b>10</b>
A. Prior to ventricular catheter insertion .....	10
B. Prepare patient for ICP catheter insertion .....	10
<b>VIII. ICP or EVD system maintenance and assessment</b> .....	<b>11</b>
<b>IX. Nursing responsibilities postplacement</b> .....	<b>12</b>
<b>X. Troubleshooting</b> .....	<b>12</b>
<b>XI. Management of EVD complications</b> .....	<b>12</b>
A. EVD infections .....	12
B. Noninfectious complication of EVD .....	16
<b>XII. EVD removal</b> .....	<b>18</b>
A. EVD weaning .....	18
B. Assisting with ventricular catheter removal .....	19
<b>XIII. Patient and family education</b> .....	<b>19</b>
<b>XIV. Lumbar drainage devices</b> .....	<b>19</b>
<b>XV. Indications for LDD placement</b> .....	<b>20</b>
A. Relative contraindications .....	20
B. Absolute contraindications .....	20
<b>XVI. LDD equipment setup</b> .....	<b>20</b>
A. Equipment needed .....	20
B. Priming the lumbar drainage system .....	20
C. Set pressure level .....	21
D. Draining CSF from an LDD .....	21

<b>XVII. LDD insertion</b> .....	<b>21</b>
A. Location for performing procedure .....	21
B. Preplacement provider evaluation .....	21
C. Prepare patient for LDD catheter insertion .....	22
D. LDD insertion .....	22
E. Potential procedural complications .....	23
F. Documentation .....	23
<b>XVIII. Nursing responsibilities postplacement</b> .....	<b>23</b>
A. Patient assessment .....	24
B. Patient care .....	24
C. System maintenance .....	24
D. Documentation .....	25
<b>XIX. LDD troubleshooting</b> .....	<b>25</b>
A. Break in the sterile system .....	25
B. Occlusion of tubing .....	25
C. No CSF drainage in collection chamber .....	25
D. Excessive CSF drainage .....	26
<b>XX. Management of LDD complications</b> .....	<b>26</b>
A. Bacterial colonization and infection .....	26
B. Meningeal irritation .....	26
C. Nerve root irritation .....	26
D. Tension pneumocranium .....	26
E. Herniation .....	26
F. Subdural hemorrhage .....	26
G. Intradural hematoma .....	27
H. Retained catheter .....	27
I. Intracranial venous thrombosis .....	27
<b>XXI. LDD removal—nursing responsibilities</b> .....	<b>27</b>
<b>XXII. Patient and family education</b> .....	<b>27</b>
<b>References</b> .....	<b>28</b>
<b>Bibliography</b> .....	<b>33</b>

## I. Introduction

### A. Problem statement and guideline goal

Nursing care of the patient with an intracranial pressure (ICP) monitoring device, external ventricular drain (EVD), or lumbar drainage device (LDD) is inherently complex as patients requiring these interventions require meticulous monitoring and multidimensional clinical decision-making. The purpose of this guideline is to assist registered nurses (RNs), patient care units, and institutions to provide safe and effective care to patients undergoing ICP monitoring via an EVD or subarachnoid drainage of cerebrospinal fluid with a LDD.

### B. Assessment of scientific evidence

In development of this guideline, nurse experts reviewed the published literature from 2000 to December 2010 using PubMed/Medline, Embase, and CINAHL, and the search included the following terms: *intracranial pressure monitoring device, intracranial pressure waveform, external ventricular drain, lumbar drain, indwelling catheters, drainage, cerebrospinal fluid, ventriculostomy, and nursing*. Monographs and textbooks were also consulted. Studies not written in English were excluded from further evaluation. Data quality was evaluated and recommendations for practice were established based on the evaluation of available evidence and expert panel consensus.

Data quality is classified as follows:

- Class I: Randomized controlled trial without significant limitations or metaanalysis
- Class II: Randomized controlled trial with important limitations (e.g., methodological flaws, inconsistent results), observational study (e.g., cohort, case control)
- Class III: Qualitative study, case study, or series
- Class IV: Evidence from reports of expert committees and expert opinion of the guideline panel, standards of care, and clinical protocols that have been identified

This CPG and recommendations for practice were based upon evaluation of the available evidence (American Association of Neuroscience Nurses [AANN], 2006):

- Level 1: Recommendations are supported by class I evidence.
- Level 2: Recommendations are supported by class II evidence.
- Level 3: Recommendations are supported by class III and class IV evidence.

## II. Anatomy and physiology

### A. Brain

The brain is protected and enclosed by the cranial vault (McCance, Huether, Brashers, & Rote, 2010)

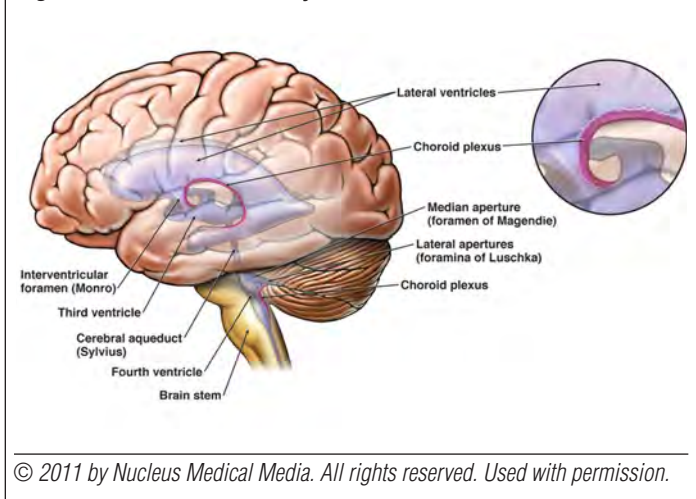
and is encased in a “layered system” that starts with the scalp as the outermost layer. The scalp is highly vascular and can bleed significantly with only minimal injury or incision. A bleeding scalp may increase the difficulty of catheter insertion. The skull is the next layer, with the thickest bones typically found in the frontal and occipital areas. Wrapping the brain and spinal cord are protective meninges composed of three layers: the dura mater, arachnoid, and the pia mater.

The dura mater is a nonelastic, membranous covering that lies above the arachnoid membrane. This covering must be pierced to place any pressure-monitoring device or catheter. The subarachnoid space is located between the arachnoid and pia mater and contains cerebral spinal fluid (CSF) (McCance et al., 2010).

### B. CSF and the ventricular system

CSF is a colorless, clear fluid produced by the highly vascular choroid plexus in the lateral third and fourth ventricles that functions as a cushion for the brain and spinal cord (Brodgelt & Stoodley, 2007; McCance et al., 2010). Approximately 500–600 ml of CSF is produced daily; about 125–150 ml circulates within the ventricular system and subarachnoid space at one time; and the remainder is reabsorbed (Brodgelt & Stoodley; Whedon & Glassey, 2009; McCance et al.). The normal amount of CSF production for infants and children is 0.33ml/kg/hr (Cartwright & Wallace, 2007).

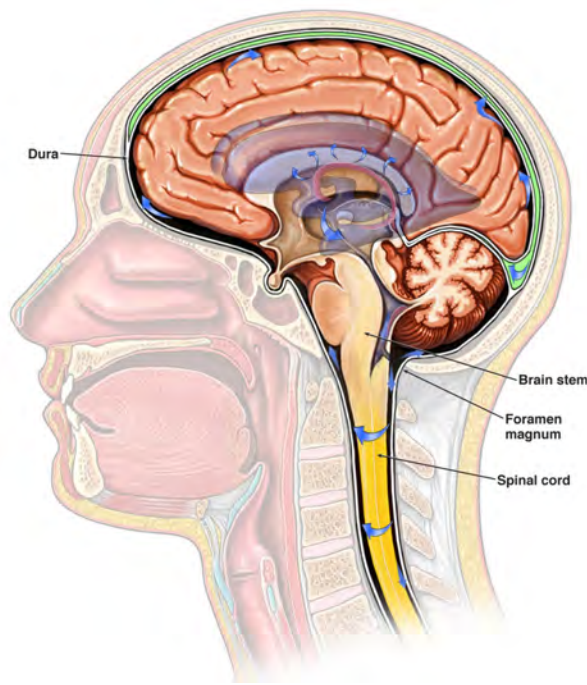
**Figure 1. The ventricular system of the human brain**



The brain’s ventricular system consists of four CSF-filled, interconnected ventricles (**Figure 1**). The largest are the two lateral ventricles, which are c-shaped cavities located in each cerebral hemisphere (Moore & Dalley, 1999). Each lateral ventricle is divided into an anterior, posterior, and

inferior horn. The third ventricle, located between the diencephalon, is continuous with the aqueduct of Sylvius, connecting the 3rd and 4th ventricles. The fourth ventricle is located in the posterior part of the pons and medulla. From the lateral ventricles, CSF flows through the intraventricular foramen (foramen of Monro), enters the 3rd ventricle, and passes through the cerebral aqueduct (aqueduct of Sylvius) into the 4th ventricle (Figure 2). As the CSF leaves the 4th ventricle, it exits through the foramina of Luschka and the foramen of Magendie, then flowing through the subarachnoid spaces of the brain and spinal cord (Figure 2).

**Figure 2. CSF flow**



© 2011 by Nucleus Medical Media. All rights reserved. Used with permission.

The subarachnoid space encompasses the entire craniospinal space; thus, CSF surrounds the entire brain and spinal cord. CSF is reabsorbed into the superior sagittal sinus (Whedon & Glassey, 2009) via the arachnoid granulations (composed of arachnoid villi), allowing for CSF to move into the venous sinuses and out into the circulation (Figure 2; McCance et al.). If reabsorption fails, CSF disorders such as hydrocephalus can occur (Brodbeck & Stoodley, 2007). Obstruction or narrowing of the CSF pathways (such as aqueductal stenosis, Chiari malformation, or cervical spondylotic disease [Komotar et al., 2008]) can make CSF removal from the lumbar space dangerous due to the risk of cerebral herniation and may also render CSF pressure

measurements inaccurate. The continuity and communication of the CSF volume in the craniospinal space allows for safe and accurate recording of CSF pressure and CSF drainage from the lumbar space (Lenfeldt, Koskinen, Bergenheim, Malm, & Eklund, 2007).

### C. Monro-Kellie hypothesis

The Monro-Kellie hypothesis provides the framework for managing and treating conditions that cause elevated intracranial pressure (ICP). This hypothesis states that because the skull is a fixed compartment containing brain tissue, blood, and CSF, the sum of these three components must remain constant: the brain parenchyma comprising 80%, CSF 10%, and cerebral blood volume 10%. An increase in any one of these components must be offset by an equal decrease in one or more components, otherwise an increase in ICP will result (Greenberg, 2006). As a result of these increases, compensatory mechanisms occur to decrease pressure in the cranial vault. These mechanisms include movement of the CSF out of the cranium and into the spinal column, additional CSF resorption into the vasculature, and compression of the venous sinuses to decrease intracranial volume (McCance et al., 2010).

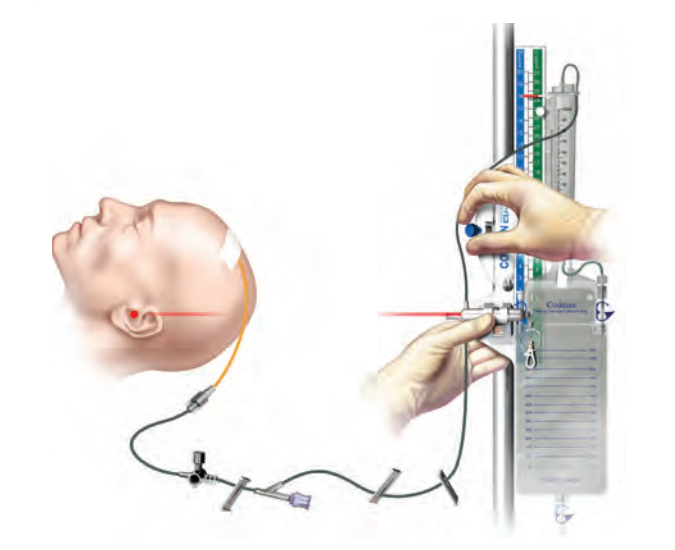
When the brain suffers an insult or injury, changes occur that affect cerebral hemodynamics, including changes in ICP, cerebral blood flow, and oxygen delivery (McCance et al., 2010). Cerebral blood flow is the amount of blood the brain requires to meet the metabolic needs and is typically approximately 15%–20% of the cardiac output (McCance et al.). Infants do not exhibit the same displacement theorized by the Monro-Kellie hypothesis because of incomplete closure of the skull and increased brain compliance.

### III. ICP monitoring and EVD

ICP monitoring is a common practice when treating intracranial pathology with risk for elevated ICP (Kirkness, Mitchell, Burr, March, & Newell, 2000). The main objective for monitoring ICP is to assess cerebral perfusion to avoid secondary injury (Bratton et al., 2007). Cerebral perfusion is the amount of pressure that is required to perfuse the cells. The only method to reliably measure cerebral perfusion pressure (CPP) and assess for cerebral hypoperfusion or intracranial hypertension is to continuously monitor ICP and blood pressure (Bratton et al.). ICP data are very useful to help predict outcomes and worsening intracranial pathology, such as cerebral edema or hemorrhage, and is useful for guiding therapy (Bratton et al.). Prophylactic administration of medications to decrease ICP, without monitoring ICP, may carry risk (Bratton et al.).

Intraventricular catheters are considered the gold standard for measuring ICP because they are placed directly into the ventricle, typically in the anterior horn of the lateral ventricle through a burr hole in the skull, and are attached to a pressure transducer (**Level 3**; Czosnyka & Pickard, 2004; Zhong et al., 2003). An external ventricular device (EVD; **Figure 3**) not only has ICP monitoring capabilities, but also can assist with controlling increased ICP by allowing for therapeutic CSF drainage (Czosnyka & Pickard; Zhong et al.). It may also be necessary to instill medications such as antibiotics and thrombolytics via the ventricular catheter for those patients with CSF infection or significant intraventricular clot volume (Kirkness et al., 2000). There are no published data to support the instillation of thrombolytics into ventricular catheter for intraventricular clot in children (Akisu et al., 2003; Gupta et al., 2001).

**Figure 3. External ventricular device**



© Copyright 2011 by Codman and Shurtleff, a Johnson & Johnson Company. All rights reserved. Reprinted with permission.

The main disadvantage to an EVD is that it is the most invasive device because it penetrates the meninges and brain, increasing risk of bacterial infection. Currently, antibiotic-impregnated and coated ventricular catheters are commercially available (**Level 2**; Muttaiya, Ritchie, John, Mee, & Roberts, 2010; Zhong et al.) to reduce this risk. Insertion requires a high degree of technical skill because there may be difficulty cannulating the ventricle, the catheter may become occluded by blood or tissue, and the need to frequently relevel in relationship to patient position (Zhong et al.).

#### A. Indications for ICP monitoring

There are many conditions that may warrant ICP monitoring. Level 1 evidence (Bratton et al., 2007) exists for ICP monitoring in people with traumatic brain injury (TBI) under certain conditions:

- Glasgow Coma Scale (GCS) score of 8 or less
- Abnormal head computed tomography (CT), age >40, posturing, systolic blood pressure <90
- Neurologic injury without clinical exam (e.g., systemic trauma, going to the operating room [OR] and under general anesthesia).

Additional conditions warranting ICP monitoring (**Level 3**; Greenberg, 2006; Czosnyka & Pickard, 2004) include

- obstructive hydrocephalus, including communicating and noncommunicating
- subarachnoid hemorrhage (SAH) resulting in acute hydrocephalus due to obstruction of arachnoid villi
- SAH Hunt and Hess grade  $\geq 3$
- cerebral edema
- surgical mass lesions
- infections (such as meningitis)
- congenital anomalies
- Chiari malformations
- brain relaxation in the OR
- benign intracranial hypertension
- craniosynostosis
- traumatic subdural hemorrhage and intraventricular hemorrhage of the newborn
- liver failure.

#### IV. Indications for EVD placement

The following conditions may progress to necessitate CSF diversion via an EVD (**Level 3**; Greenberg, 2006; Czosnyka & Pickard, 2004):

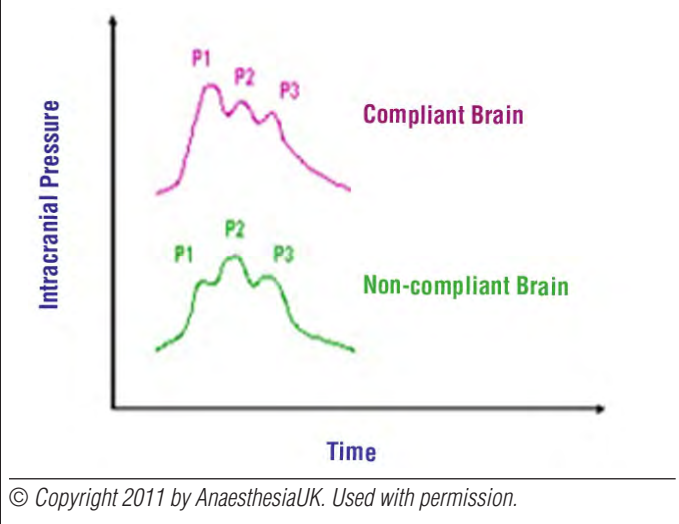
- obstructive hydrocephalus, including communicating and noncommunicating
- SAH resulting in acute hydrocephalus due to obstruction of arachnoid villi
- SAH Hunt and Hess grade  $\geq 3$
- cerebral edema
- surgical mass lesions
- infections (such as meningitis)
- Chiari malformations
- shunt failure due to mechanical disruption or infection
- brain relaxation in the OR.

#### V. ICP waveform analysis

ICP monitoring not only allows for measuring of ICP but also provides information about intracranial dynamics and brain compliance from waveform assessment. ICP waveform analysis provides information that may identify patients with decreased adaptive capacity who are at risk for increases in ICP and decreases in CPP (Czosnyka & Pickard, 2004; Kirkness et al., 2000). The ICP waveform (**Figure 4**) has three components: pulse, respiratory, and "slow waves" (Czosnyka & Pickard). The pulse component of a normal ICP waveform generally consists of three peaks, decreasing in height to correlate with the arterial

pressure waveform occurring with each cardiac cycle (Kirkness et al.). These pulse waves represent arterial pulsations in large cerebral vessels as they produce a fluctuation in the volume within the ventricles (Ravi & Morgan, 2003). P1, the first and sharpest peak, is called the “percussive wave” and results from arterial pressure being transmitted from the choroid plexus. P2, the second peak, referred to as the “tidal wave,” varies in amplitude with brain compliance and ends on the dicrotic notch. P3 represents the “dicrotic wave” and is caused by closure of the aortic valve (Figure 4; Kirkness et al.). Some individuals may have additional peaks, but these are not as clinically significant as the three main peaks (Kirkness et al.). The respiratory waveform is a slower pattern in synch with the patient’s breathing as it reflects changes in intrathoracic pressure associated with respiration (Czosnyka & Pickard; Kirkness et al.). The respiratory waveform generally is about 8–20 cycles per minute.

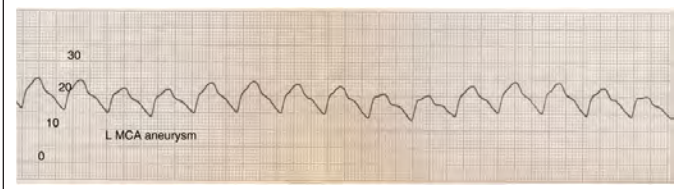
**Figure 4. ICP waveform**



Analysis of the ICP waveform begins with understanding its shape and amplitude. The shape of the ICP waveform resembles the shape of the arterial waveform. The amplitude, or height of the waveform, varies with changes in physiologic state and is influenced by changes in intracranial compliance and cerebral blood flow (Ravi & Morgan, 2003). As the ICP increases due to an excess of components within the cranial vault, the amplitude of P1, P2, and P3 all increase, but if the ICP continues to rise, P2 becomes more elevated than P1 until eventually P1 may disappear within the waveform (Kirkness et al., 2000). This signifies a decrease in intracranial compliance and may warrant intervention. Elevation of P2 can also indicate the patient will have a rise in ICP with stimulation (Fan, Kirkness, Vicini, Burr, & Mitchell, 2008). Arterial hypotension and hypertension affect the amplitude of P1; severe hypotension causes a decrease in amplitude whereas severe hypertension causes an increase in amplitude (Kirkness et al.). Amplitude increases as compliance decreases, which will be evident prior to the actual

elevation in ICP (Kirkness et al.; Ravi & Morgan). Conditions resulting in a constriction of cerebral blood vessels, as seen with hypocapnia or vasospasm, will exhibit a decrease in the amplitude of the waveform whereas conditions of severe hypercapnia and hypoxia will exhibit an increase in amplitude with an inability to distinguish the individual waves due to a rounding appearance of the waveform (Figure 5; Kirkness et al.). Patients who have undergone a craniectomy (bone flap removal) will have a dampened waveform (Kirkness et al.). In addition, the waveform will be dampened for newborn patients due to incomplete skull fusion.

**Figure 5. Rounding of ICP waveform due to aneurysmal vasospasm**



© Copyright 2011 by Karen March. Used with permission.

**Table 1. ICP changes related to differing physiologic conditions**

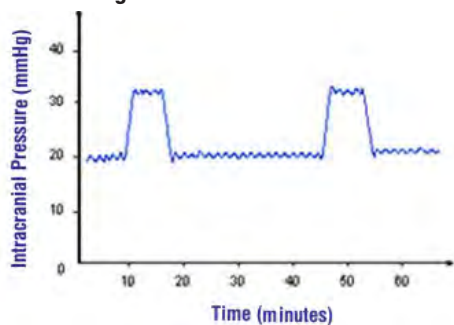
Condition	ICP Changes
Rapidly expanding mass lesion	Increase mean ICP Increase ICP waveform amplitude
Increase/decrease CSF volume	Increase/decrease mean ICP Increase/decrease ICP waveform amplitude Little change in ICP waveform configuration
Severe arterial hypotension	Decrease mean ICP Decrease ICP waveform amplitude, especially P1
Severe arterial hypertension	Increase mean ICP Increase ICP waveform amplitude
Severe hypercapnia and hypoxia	Increase mean ICP Increase ICP waveform amplitude Rounding of ICP waveform due to increase in later waveform components
Hyperventilation	Decrease mean ICP Decrease ICP waveform amplitude P2, and to a lesser degree, P3 with little change in P1
Jugular vein compression	Increase mean ICP Increase ICP waveform amplitude, mainly P2 and P3

From Kirkness, C. J., Mitchell, P. H., Burr, R. L., March, K. S., & Newell, D. (2000). *Intracranial pressure waveform analysis: Clinical and research implications*. *Journal of Neuroscience Nursing*, 32, 271–277. Used with Permission.

When ICP is elevated and there is a decrease in intracranial compliance, pathologic waves (Lundberg waves) may appear (Lemaire et al., 2002). Lundberg described these as A, B, and C waves. Due to the current types of monitors used, these waveforms are hard to distinguish because they are assessed as a trend over time; with most current technology, the mean ICP number is used (Lemaire et al.).

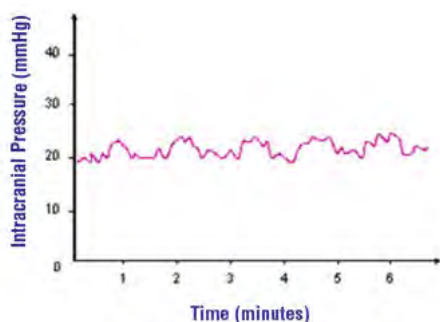
“A” waves, referred to as “plateau waves,” are characteristic of conditions that create a state of low intracranial compliance (Figure 6; Lemaire et al., 2002) and result from vasodilation of cerebral blood vessels as the body responds to a decrease in cerebral perfusion pressure (CPP; Ravi & Morgan). As ICP increases, the “A” waves reflect steep increases in this pressure, lasting as long as 5–20 minutes before rapidly declining (Ravi & Morgan). They have been associated with poor outcomes related to cerebral hypoxia, ischemia, infarction, and herniation; therefore, the presence of these waves should prompt treatment of ICP (Level 3; Hickey, 2009). “B” waves are of less clinical significance but are characterized as intermittent pathological waves whose amplitudes sharply rise and fall every 1–2 minutes depending on changes in cerebral blood volume seen with decreased compliance (Figure 7; Ravi & Morgan). These waves can be seen with Cheyne-Stokes breathing pattern or during periods of apnea and may present prior to “A” waves, indicating the need to treat elevated ICP (Level 3; Hickey, 2009). “C” waves are not thought to be of clinical significance (Ravi & Morgan).

**Figure 6. Lundberg A waves of ICP**



© Copyright 2011 by AnaesthesiaUK. Used with permission.

**Figure 7. Lundberg B waves of ICP**



© Copyright 2011 by AnaesthesiaUK. Reprinted with permission.

## VI. EVD equipment setup

A. Equipment needed (See **Appendix A** for sample EVD cart checklist.)

In preparation for insertion, the nurse should gather the following equipment:

- intracranial access kit
- ventricular catheter
- external ventricular drainage system
- flushless transducer
- pressure cable and module
- sterile prep kit, or antimicrobial scrub solution
- sterile gloves, gown, mask, and cap
- sterile drapes
- electric or disposable clippers
- sterile preservative-free normal saline (0.9%) in a 30 or 40 mL syringe.

B. Priming the EVD

Ventricular drainage system manufacturers recommend priming the system prior to attaching it to the patient’s catheter. Failure to prime the EVD tubing results in variable CSF flow speeds as it travels through the tubing and the risk that air bubbles will collect and change the flow of fluid from the patient to the collection bag and cause inaccurate pressure readings (Littlejohns & Trimble, 2005).

The ICP monitor and drainage devices arrive from the manufacturer with all stopcocks in the “neutral” position. Variations in transducer placement on the device will determine positioning of the “off” marker on the stopcocks.

The monitoring system should be primed with sterile preservative-free normal saline (0.9%). (Level 3; Littlejohns & Trimble). The monitoring device should be secured to an intravenous (IV) pole at the patient’s bedside. The device may be hung on an IV pole using the cord attachment or secured with a pole clamp and the cord attachment. For patient safety, priming the device should be accomplished by attaching a 30-mL (or smaller) syringe filled with sterile preservative-free normal saline to the patient line stopcock using sterile procedure (Level 3; Tanner, Woodings, & Moncaster, 2006). The use of IV infusion bags or pressure bags to prime the system is not recommended because the risk of inadvertent injection into the brain creates a safety risk for the patient. Further, manufacturer recommendations preclude the use of IV solutions or pressure bags.

Procedure for priming EVD tubing:

- Attach flushless transducer to the panel mount stopcock.
- Using sterile procedure, attach the syringe to the patient line stopcock (distal aspect of tubing; Tanner, Woodings, & Moncaster).

- Rotate the stopcock position “off” toward the drainage device.
- Slowly inject the sterile preservative-free saline toward the distal aspect (patient end) of the tubing. When the fluid has reached the distal end of the tubing, allow several drops of fluid to exit the end of the tubing to ensure there are no air bubbles in the tubing. Note: Many systems do not require that the end cap be removed to prime the tubing. Please check with manufacturer.
- Keeping the syringe in place, rotate the stopcock “off” to the distal aspect of tubing. Ensure that the panel mount stopcock is “open” to the flushless transducer. Prime through the vented caps in the flushless transducer. Replace vented caps with dead-end caps.
- Keeping the syringe in place, rotate the stopcock “off” to the transducer and prime fluid into the graduated burette.
- After priming, the stopcock on the distal patient line should remain “off” to the distal aspect to ensure no fluid leaks from the system prior to the healthcare provider connecting the drainage device.
- The drainage device and the catheter from the patient are connected by the qualified healthcare provider using sterile procedure.

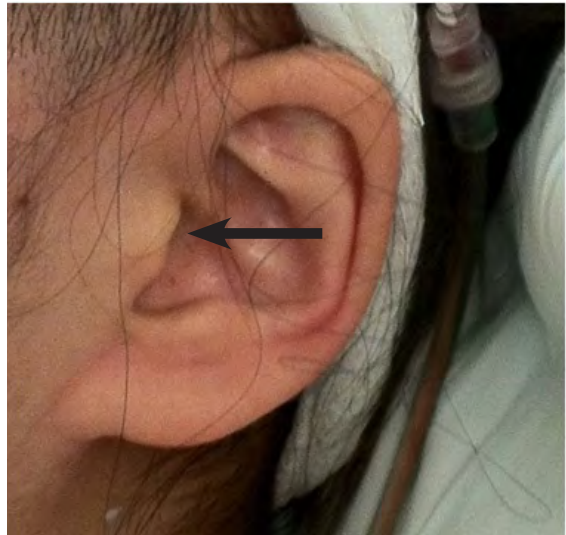### C. Zeroing and calibrating the EVD

The ICP monitoring system connects to the bedside patient monitor with a pressure cable plugged into a designated pressure module. The benefit of fluid-coupled systems is the ability to zero the device after insertion. However, these devices may require the nurse to recalibrate at intervals after the system is in use. The transducer is rezeroed after a shift (minimally every 12 hours), as a troubleshooting technique, or when interface with the monitor has been interrupted. The transducer should not require rezeroing when repositioning the patient.

#### 1. Set zero reference level

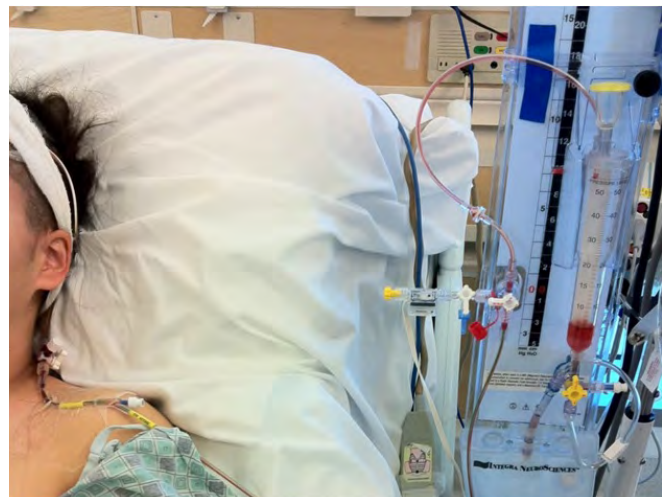Raise or lower the system to the appropriate anatomical landmark. This should correspond to the zero reference mark on the EVD device. The standard location to measure ICP is at the level of the Foramen of Monro. The landmark to approximate the Foramen of Monro is nearly as varied as the institutions using ICP monitoring devices. The key to accurate ICP measurement is to use the same landmark each time; for example, tragus of the ear (**Figure 8**) or outer canthus of the eye. It is recommended that each institution use one landmark for EVDs (**Figure 9**).

**Figure 8. Anatomical location of tragus**



© Copyright 2011 by AANN. All rights reserved.

**Figure 9. Transducer leveled with the tragus**



© Copyright 2011 by AANN. All rights reserved.

Some intracranial monitoring systems use a laser-leveling device to provide the nurse with a quick way to level the system (Figure 3). Other leveling tools include carpenter or string levels. Use caution to ensure the laser light does not shine into the patient’s eyes or the eyes of other staff or visitors who may be present in the room. If the laser-leveling device includes a bubble level, ensure the bubble is within the markings to position the system correctly.

#### 2. Set pressure level

Leveling the fluid-filled EVD is the basis for controlling ICP. When the ICP is higher than the prescribed pressure level, CSF will drain

into the graduated burette. Hydrostatic pressure dictates CSF drainage. The fluid column pressure must be greater than the weight of the CSF in the system before drainage occurs. The pressure level (on the graduated burette) is prescribed by a qualified healthcare provider. Procedure:

- Set pressure level (noted on the graduated burette) according to the qualified healthcare provider's orders

3. Zero transducer to atmospheric pressure  
Procedure:

- Turn the transducer stopcock "off" to the patient and remove dead-end cap ("off" to patient, "open" to air).
- Press the "zero" button on the bedside monitor.
- The nurse should note a cue on the monitor for successful calibration of the system.
- If the bedside monitor does not automatically calculate the CPP, the nurse may obtain the value by subtracting the mean arterial pressure (MAP) from the ICP ( $MAP - ICP = CPP$ ).

#### D. Obtaining ICP tracing

Turn the panel mount stopcock "off" to the drain and "open" to the transducer to obtain an accurate ICP numerical value and waveform. The ICP numerical value and waveform should be obtained every hour. If there is an increase in intracranial pressure, then the value should be obtained more often (i.e., every 15 minutes).

#### E. Draining CSF

There are different methods for CSF drainage. One method is to keep the EVD stopcock "off" to drain and "open" to the transducer for continuous ICP monitoring. When the ICP reaches a specified pressure, "open" the stopcock to drain CSF for a short time period. Another method is to continually allow CSF drainage and perform intermittent ICP readings. The amount of CSF drainage is controlled by raising the pressure level on the graduated burette above the Foramen of Monro, which is the zero reference level. Choosing one method over the other depends on the patient's pathology. For example, intraventricular hemorrhage usually requires continuous CSF drainage. Both practices require an order from the healthcare provider. Accurate ICP readings are only taken when the stopcock is turned "off" to drainage.

Note: These systems allow practitioners to drain CSF or monitor ICP. They do not allow practitioner's to drain CSF and monitor ICP simultaneously.

## VII. Ventricular catheter insertion

### A. Prior to ventricular catheter insertion

Ensure informed consent has been obtained from the patient or appropriate legal designee. Assist the physician in explaining to the patient, family, and significant others benefits and risks of using ICP monitoring catheters. Inserting ICP monitoring catheters may pose a risk for clinically significant cerebral hemorrhage (**Level 2**; Brain Trauma Foundation [BTF], 2007). An international normalized ratio (INR) of 1.2–1.6 was found to be acceptable for ventriculostomy placement in adults (**Level 2**; Davis et al., 2004; Bauer, McGwin, Melton, George, & Markert, 2011). There is no published evidence for acceptable INR range prior to EVD placement for the pediatric population. Interventions would need to occur prior to device placement, such as transfusion with fresh frozen plasma (FFP; Greenberg, 2006).

Insertion of ICP catheter may occur in the OR, emergency room, radiology department, or intensive care unit. All ICP catheters should be inserted using sterile technique. Interestingly, intracranial catheters inserted outside of the OR show a tendency toward higher infection rates (Arabi et al., 2005).

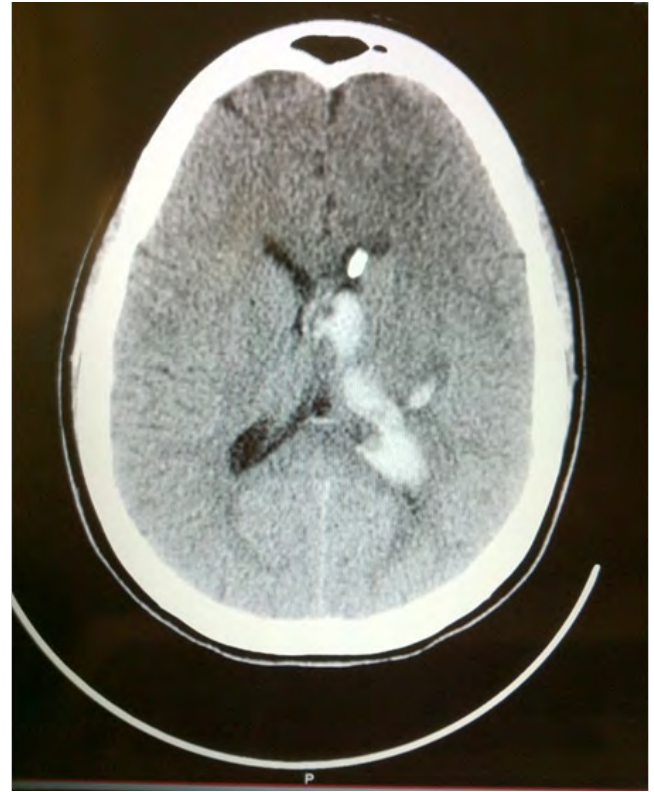### B. Prepare patient for ICP catheter insertion

- The patient should be positioned with the head of bed (HOB) elevated at 30 degrees with the head in a neutral position (**Level 2**; Fan, 2004). Immobilize the head to prevent patient movement and facilitate catheter insertion.
- Obtain, prepare, and administer analgesia and sedative as ordered by the healthcare provider (**Level 2**; BTF).
- During the insertion, the nurse should continually monitor heart rate and rhythm, respiratory rate, and pulse oximetry, and frequently monitor blood pressure throughout the procedure (**Level 2**; Fan). Consider recommending insertion of an arterial blood pressure monitoring catheter if not already available because vigilant monitoring of mean arterial blood pressure (MABP) is necessary to avoid decreased CPP (**Level 3**; Fan). Analgesia and sedatives may cause hypotension (BTF). Perform neurological assessments every 15 minutes during the insertion process because serial assessments are necessary for immediate identification of neurologic changes and earlier initiation of treatment (**Level 3**; Arbour, 2004; Barker, 2008).
- Wear personal protective equipment (PPE). Ensure all clinicians in close proximity of the

patient have appropriate PPE on during the insertion process because PPE may prevent contamination of equipment and insertion site and protect clinicians from exposure to patients' blood and tissue (**Level 2**; Association of periOperative Registered Nurses [AORN], 2009; March & Madden, 2009).

- Perform “time out” per universal protocol. Insertion site depends on type and location of injury. Generally, catheters are inserted in the patient’s nondominant side of the brain in the frontal lobe (Arbour, 2004; Stefani & Rasulo, 2008).
- Site preparation and draping may be performed by a trained registered nurse or healthcare provider.
  - Braid or clip hair (AORN). If clipped, use a sticky paper product (tape) or something similar to remove residual hair clippings.
  - Clean site in circular motion with antiseptic solution. Note: The U.S. Food and Drug Administration (FDA) and package insert warn against use of 2% chlorhexidine preparation when there is possible contact with the meninges.
  - Drape areas surrounding the site with sterile towels.
- The physician or other credentialed provider gains access to the cranium and inserts the ICP catheter using the following procedure:
  - The scalp is infiltrated with lidocaine HCl.
  - With scalpel, a small (1 cm) incision is made in the scalp and subcutaneous tissue.
  - A hole is drilled through the cranium, followed by a rinse with sterile, preservative-free normal saline.
  - An 18-gauge spinal needle is used to puncture the dura and is then removed.
  - The ICP catheter is inserted through the burr hole to the desired depth (lateral ventricle, intraparenchymal, subarachnoid, subdural, or epidural space) with a catheter over a stylus or through a sheath screwed into the burr hole in the skull.
  - The catheter is secured using a tunneling method through a separate incision and sutured.
  - A CT scan may then be performed to confirm catheter placement (**Figure 10**; Barker, 2008; Ehtisham, Taylor, Bayless, Klein, & Jantzen, 2009; Kakarla, Kim, Chong, Theodore, & Spetzler, 2008; Ko & Conforti, 2003; Koskinen & Olivecrona, 2005; Stefani & Rasulo, 2008).

**Figure 10. CT scan with EVD catheter placed in left lateral ventricle**



© Copyright 2011 by AANN. All rights reserved.

Note: This patient could not have the catheter placed in the nondominant hemisphere due to a lesion that was appreciated in another CT slice.

### VIII. ICP or EVD system maintenance and assessment

Patients who require an EVD should be closely monitored by nurses trained and competent in assessment and management of both the drain and the neuroscience patient population (**Level 3**; expert panel consensus). Patient assessment should include monitoring for signs and symptoms associated with changing ICP. Increases in ICP may be characterized by decreased level of consciousness, nausea, vomiting, headache, lethargy, or agitation (Greenberg, 2006). Neurological assessments should be performed and documented hourly by the registered nurse, or more frequently as the clinical situation warrants (**Level 3**; expert panel consensus). Notify the physician immediately if ICP exceeds established parameters. If no parameter is specified, notify the physician if ICP is >20 mmHg.

Assessment of the drainage system should be done a minimum of every 4 hours, which includes inspecting the EVD from the insertion site along the entire drainage system, checking for cracks in the system or fluid leaking from the insertion site (**Level 3**, expert panel consensus). Hourly assessment includes obtaining mean ICP, CSF drainage, color, and clarity. Ensure the system is appropriately clamped or open depending on patient situation and physician order. Check patient position to

ensure transducer is at the ordered reference level. If the patient is very active and moving around in bed, it is imperative to frequently assess that the drain is leveled appropriately to prevent over- or under-drainage. Check EVD for patency as needed by lowering the entire system for a brief moment to assess drip rate into the graduated burette. Waveform assessment should be ongoing with special attention noted to P1, P2, and P3 components. Be aware of changes in waveform and troubleshoot when warranted. Document ICP waveform assessment once a shift and as waveform changes occur. Perform waveform analysis upon initial assessment of patient and system, establishing a baseline to use for comparison throughout the shift. Observe ICP in relation to other hemodynamic parameters such as MAP, which will give an indicator of CPP (**Level 3**, expert consensus).

#### IX. Nursing responsibilities postplacement

- Assist physician to connect catheters to monitoring equipment while maintaining sterility and preventing contamination of site, catheters, and the sterile field.
- Although a common practice, irrigation of insertion site with antibiotic solution or application of antimicrobial ointment at time of insertion does not significantly affect the infection rate and is therefore not recommended (**Level 3**; Arabi et al., 2005).
- Dress insertion site by applying sterile dressing (Barker, 2008; Ehtisham et al., 2009).
- Begin monitoring ICP (See section on ICP monitoring and EVDs on page 5.)
- Obtain an ICP pressure tracing.
- Document patient tolerance to insertion process, including neurologic assessments, vital signs, pulse oximetry, medication administration, and ICP.
- Dispose of insertion instruments and equipment as appropriate. Proper handling of patient-contaminated equipment will prevent clinician exposure (**Level 2**; AORN; March & Madden, 2009).

#### X. Troubleshooting

Troubleshooting the EVD and drainage system is done in a methodical manner, beginning from the drain and working along the line toward the patient, or from the catheter insertion site and working distally to the drainage system. Careful attention is paid to the catheter to assess for kinks and the drainage tubing to look for air bubbles, blood clots, or debris that could be blocking the free-flow of CSF or causing a dampened waveform.

An absence of an ICP waveform may be the result of air bubbles, clots, or debris within the drainage tubing or across the transducer. A malfunctioning pressure cable, module, or transducer may also result in the loss of the ICP

waveform. The nurse should perform a systematic assessment of the system to rule out the presence of air or debris in the tubing (**Level 3**; Woodward et al., 2002). The next steps are to ensure that the drain is leveled at the appropriate landmark and the system is rezeroed. If this fails to establish the ICP waveform, the pressure cable, module, or transducer may need to be replaced. In this event, the nurse should begin by changing only one item at a time, such as the cable.

#### XI. Management of EVD complications

##### A. EVD infections

Infection associated with EVD is the major complication reported in the literature. The definition of EVD-associated or nosocomial ventriculitis and meningitis has been much debated, and there is no definite agreement (Pfausler et al., 2004; Scheithauer et al., 2009). A wide range of infection rates are reported in the literature; however, the mean EVD-associated infection rate is 8%–9% (Fichtner, Güresir, Seifert, & Raabe, 2010; Lozier, Sciacca, Romagnoli, & Connolly, 2002; Zambranski et al., 2003). The difficulty with defining and making the diagnosis is that conditions frequently requiring ICP monitoring, such as subarachnoid hemorrhage, traumatic brain injury, or neurosurgical procedures, often also result in a chemical irritation of the meninges from the blood in the CSF spaces. Blood initiates a strong inflammatory response by activating leukocytes. The activated leukocytes move in to phagocytose the blood. The inflammatory response, called aseptic or chemical meningitis, has clinical characteristics indistinguishable from the clinical signs of bacterial meningitis (British Society for Antimicrobial Chemotherapy, 2000; Lozier et al.; Scheithauer et al.).

Standard CSF analysis is not specific or sensitive enough to differentiate between aseptic or bacterial meningitis (**Level 2**; Leib, Boscacci, Gratzl, & Zimmerli, 1999; Schade et al., 2006; Zarrouk et al., 2007). Patients who have received antibiotics or steroids have CSF laboratory values less specific for identifying bacterial meningitis (Leib et al.; Wong & Poon, 2008). Empiric broad spectrum antimicrobial therapy is initiated when CSF analysis and clinical signs of meningitis together indicate infection (Beer, Pfausler, & Scmutzhard, 2009; Schade et al., 2005; van de Beek, Drake, & Tunkel, 2010). Nosocomial bacterial meningitis in postneurosurgical patients may lead to a high mortality rate if it is not recognized and treated early; mortality rates of 16%–30% have been reported (Chang et al., 2008; Weisfelt, van de Beek, Spanjaard, & de Gans, 2007; Zarrouk et al., 2007).

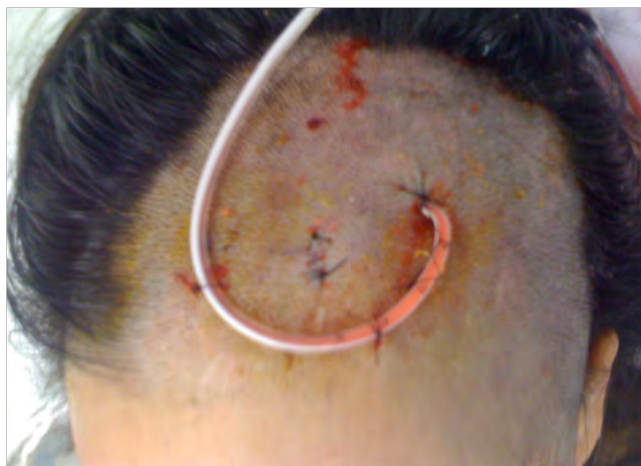1. Prevention of infection and strict adherence to aseptic technique

Prophylactic antibiotics remain controversial due to the risk of selection for resistant organisms (Arabi et al., 2005; Frontera et al., 2008; Lozier et al., 2002). The BTF guidelines (2007) do not recommend administering antibiotics prior to placement of ICP monitoring devices. Ventricular catheters are placed in an emergent situation and prophylactic antibiotics cannot be administered in a timely manner. A single preoperative dose should be given 30 minutes prior to incision but not more than 2 hours before incision (Connolly, McKhann, Huang, & Choudhri, 2002; Dellinger et al., 1994).

Antibiotic-impregnated ventricular catheters have been widely used after a randomized multicenter clinical trial showed evidence of their ability to reduce infections (Zambranski et al., 2002). These catheters have been criticized for potentially showing false negative CSF cultures or increasing resistant infections. Technological solutions to infection can be beneficial but do not replace proven infection control practices. The successful reduction of EVD-associated infection may have relaxed many institutions' high vigilance for prevention.

Tunneling is a technique frequently used to decrease EVD infection (Dasic Hanna, Bonjanic, & Kerr, 2006; Lozier et al., 2002). This is the same technique that allows Groshong central access catheters to remain in place for long periods without infection. The ventricular catheter is tunneled under the scalp approximately 5 cm away from the insertion site. Tunneling has the additional benefit of helping to secure the catheter. The catheter is also sutured to the scalp (usually in two locations; **Figure 11**).

**Figure 11. Sutured EVD catheter**



© Copyright 2011 by AANN. All rights reserved.

### Recommendations:

- Placement of any ICP monitoring device should be performed under conditions that model the operating room with maximum barrier protection. The doors should be closed, all people in the room should wear hats and masks, and the sterile field should be protected. EVD placement is frequently performed urgently, but care should be taken to maintain sterility. Contamination often occurs on the skin tract at placement (**Level 2**; Dasic et al. 2006). A designee should assist with catheter placement by holding the patient's head (**Level 2**; Leverstein-van Hall et al., 2009).
- Manipulation and accessing of the EVD drainage tubing have been shown to be sources for bacterial contamination (**Level 2**; Hoefnael, Dammers, Ter Laak-Poort, & Avezaat, 2008; Korinek et al., 2005; Lozier et al.). The risk of CSF infection increases with the duration of the EVD (**Level 2**; Lozier et al.; Mayhall et al., 1984; Schade et al., 2005). Therefore, access of the EVD for CSF sampling should occur when infection is suspected (See **Appendix B** for sample policy and procedure).
- Institutional practices vary on whether EVD tubing manipulation is a nursing or physician practice (Hoefnagel et al., 2008; Korinek et al., 2005; Muttaiyah, Ritchie, Upton, & Roberts, 2008). This high-risk procedure requires an institutional commitment to training and staff competency (**Level 3**; Criddle, 2007).
- No specific studies on cleaning of EVD access ports were found and research is needed on this topic. The best data supporting the cleaning of EVD access ports are from the vascular access device literature, but this is also limited. The CDC recommends alcohol for cleaning vascular access ports; povidine-iodine is also acceptable (**Level 3**; Meyer, 2009). Chlorhexidine-alcohol has been shown to be an effective antiseptic for topical skin preparation (**Level 1**; Darouiche et al., 2010; Hibbard, 2005). For neurosurgical procedures, it has been shown that a 3-minute cleaning with chlorhexidine-alcohol followed by two 30-second cleanings with povidine-iodine is highly effective for sterilizing the skin (**Level 1**; Guzel et al., 2009). The combined effect of three disinfectants—chlorhexidine, alcohol, and povidine-iodine—would have the broadest bactericidal effect but the FDA

has not approved chlorhexidine for purpose of cleaning access ports (Meyer, 2009).

- The drainage tubing should not be routinely changed; it should remain for the duration of the EVD (**Level 3**, expert panel consensus). The initial sterility of the drainage tubing must be meticulously ensured. A two-person method is ideal for priming the tubing with sterile normal saline. The second person should monitor the sterile technique and help if needed. Use a sterile barrier to assemble the drain, wear masks and hats, and wash hands before applying sterile gloves.
  - If the EVD drainage tubing accidentally becomes disconnected, every effort should be made to maintain the sterility of the ventricular catheter. New sterile EVD tubing should be obtained and connected (**Level 3**, expert panel consensus).
  - Follow strict aseptic technique when the EVD is accessed or irrigated, and use hand hygiene, mask, sterile field, and sterile gloves. Scrub the EVD access port 3 minutes with povidine-iodine or follow individual institutional policy (**Level 3**; Meyer, 2009; Pope, 1998; See Appendix B for sample policy and procedure).
  - Maintaining CSF flow has been suggested as a method to avoid ascending infection (**Level 2**; Razmkon & Bakhtazad, 2009).
  - Any contamination of the collection bag can be transferred upward and is avoided by following sterile technique. When changing the collection bag, wear sterile gloves and a mask. Only change the bag when it is nearly full (**Level 3**; Bader, Littlejohns, & Palmer, 1995; Korinek et al., 2005; Pope, 1998). Change the bag when it is  $\frac{3}{4}$  full (**Level 2**, Leverstein-van Hall et al., 2010; Thompson, 2000)
  - The collection system should be maintained in the upright position. If for some reason the collection chamber has to be laid down (for example, there is no MRI-compatible holder), the CSF should be drained into the lower collection bag. This will decrease the transfer of any bacteria in the collection chambers to the drainage tubing (**Level 3**; Woodward et al., 2002).
  - Hand hygiene, gloves, and a new sterile dead-end cap should be used to zero the transducer when necessary after transport. To clear air off the transducer again, wash hands before gloves then drain CSF off into sterile gauze and rezero the transducer (**Level 3**, expert panel consensus).
- The EVD tubing access port should be clearly labeled as EVD. It has been repeatedly documented that three-way stopcocks and other EVD ports have been accidentally mistaken for intravenous lines (**Level 3**; Drake & Crawford, 2005; Howell & Driver, 2008; Legal Eagle Eye Newsletter, 2007). It is recommended that manufacturers design access ports so that these types of human errors are not possible.
  - EVD wound dressings and hair-removal practices vary widely. After implementing an education program to teach nursing staff a strict sterile dressing change procedure, one facility experienced a 78% decrease in infection rate (**Level 3**; Craighead et al., 2008).
  - An occlusive dressing is placed to cover both incisions. The initial dressing is removed every 48 hours or if soiled per institutional policy. The nurse removes this initial dressing with sterile gloves and also wears a mask. If the hair grows out, the nurse clips it again so that the gauze dressing adheres. The site is inspected for CSF leaks or infection. The nurse then removes the first pair of gloves. Hand hygiene is then performed for a second time before applying a new, second set of sterile gloves. A new sterile gauze dressing is applied to the site, and benzoin is used to hold the tape. The dressing is tight and occlusive. (**Level 3**; Craighead et al., 2008).
  - For EVD-associated infection rates greater than 10%, it is recommended the institution should investigate its practices and EVD protocols (**Level 3**; Lozier et al.).
  - CSF leaks represent a site for bacterial entrance and, when discovered, are important to report (van de Beek et al., 2010).
    - When the EVD is removed, the site should be monitored for a CSF leak. An additional suture may be needed to close the skin incision. There is a high risk for infection with CSF leak after EVD removal, so careful monitoring postremoval is warranted (**Level 2**; Korinek et al., 2005).
    - No IV tubing or cords that could cause tension should be allowed on top of the EVD tubing.
    - If the EVD is accidentally removed, occlusive pressure should be held at the site.
2. Clinical signs of bacterial ventriculitis and meningitis in EVD-associated infection

Daily CSF surveillance may expose the EVD to contamination and should be avoided (**Level 2**; Hoefnagel et al., 2008; Korinek et al., 2005). Clinical suspicion of CSF infection is a reason to send CSF samples for analysis. In a study of 50 episodes of nosocomial meningitis, more than 70% of patients had headache, stiff neck, and fever (Weisfelt et al., 2007). In a report of 106 postneurosurgical meningitis cases, there was altered mental status in 55% and a seizure rate of 26% (Chang et al., 2008). The classic symptoms of bacterial meningitis—fever, stiff neck, headache, and a decreased level of consciousness—can all commonly be seen in neurologically injured critical care patients and, while common in infections, are not specific to them.

Meticulous attention to the detailed neurological examination by the neuroscience nurse can lead to early identification of cerebral infection. In the neurological patient there are numerous causes of fever; however, only 7% were attributed to meningitis or ventriculitis in a study of subarachnoid hemorrhage and fever (Fernandez et al., 2007). The neuroscience nurse will notice if the headache pattern is changing and investigate the many possible sources of fever. Other clinical signs of CSF infection are nausea, vomiting, mental status changes—such as confusion or irritation—and cranial nerve palsies. Hearing loss has been reported in about 10% of meningitis cases (Weisfelt et al., 2007; van de Beek et al., 2004). Diplopia with cranial nerve (CN) VI palsy has also been reported (van de Beek et al.). CN III and VII palsies have been less commonly reported (van de Beek et al.). Purulent drainage at the EVD entrance site and cloudy or purulent CSF are overt signs of infection.

Gram-negative bacterial infection will commonly present with a strong inflammatory response and clinical signs (Muttaiyah et al., 2008). The most common bacteria associated with EVD infections are gram-positive skin flora (*staphylococci*). Initially, infection can result in a weak inflammatory response (Beer et al., 2008; Muttaiyah, Lackner, Pfausler, & Scmutzhard, 2008). In pediatric patients, clinical signs of infection were evident before laboratory findings (Hader & Steinbok, 2000). The elderly may present with less clear clinical signs and only show a decreased level of consciousness (Tunkel, 2009). Bacterial meningitis primarily affects the subarachnoid space, whereas the inflammatory response affects the cerebral vessels and can lead to vasospasm or thrombus formation (Gray & Fedorko, 1992; Sexton, 2009; Tunkel &

Scheld, 1993). The increased permeability of the blood-brain barrier in response to the presence of bacteria can lead to vasogenic cerebral edema. Cytotoxic cerebral edema is caused by the bacteria and neutrophil action (Tunkel & Scheld).

#### Recommendations:

- New or increasing headache, nuchal rigidity, and decreased level of consciousness or cranial nerve signs are reasons to send CSF for infection surveillance (**Level 2**; Arabi et al.; Frontera et al., 2008; Hoefnagel et al.; Schade et al., 2006; van de Beek).
- Persistent and recurrent fever indicates the need to investigate for CSF infection. Positive CSF culture is highly correlated with fever (**Level 2**; Chang et al., 2008; Wisfelt et al., 2007; Schade et al.).

#### 3. CSF analysis

EVD-associated infection is defined by a positive CSF culture (Gray & Fedorko; Lozier et al., 2002; Mayhall et al., 1984; van de Beek et al.). This test is not ideal because microbiology incubation periods may be long, and prior antibiotic therapy can also result in false negative results. Colonization of the catheter or contamination of the sample can occur without infection and would be distinguished by a lack of clinical indicators (Schade et al., 2005). Gram stain has a low sensitivity but when it is positive it can direct empiric antibiotic therapy sooner than a culture (Leverstein-van Hall et al., 2010; Schade et al., 2006; Tunkel, 2009). Normally, there are very few white blood cells (WBC) in the CSF, fewer than five WBC and no neutrophils. An increasing ratio of WBC to red blood cells (RBC), normally 1:500, may be an early indication of infection in patients with hemorrhage (Pfausler et al., 2004; Boer, Siegmund, Pfister, Isenmann, & Deufel, 2008). In hemorrhage, gross contamination of the CSF with blood results in an increased WBC level. Inflammatory processes bring additional WBCs into the CSF. The WBC count is high in nosocomial bacterial meningitis but there is such a great range that no specific count is relevant (Zarrouk et al., 2007).

The increased ratio of WBCs to RBCs, together with a low CSF glucose is a strong indicator of CNS infection. CSF glucose is normally 60% of blood glucose and should be at least 45mg/dL. Decreasing CSF glucose levels can occur with bacterial invasion of the subarachnoid space as the bacteria consume glucose. A ratio of CSF glucose to serum glucose less than 0.4 is predictive of bacterial

infection (Leib et al., 1999). When CSF labs are sent, serum glucose should also be done. If a serum glucose level is not available, a CSF glucose less than 18 mg/dL is predictive of bacterial growth (Johnson & Sexton, 2009).

Increased CSF protein is not specific to meningitis and is not useful in identifying early infection in the patient with EVD and hemorrhage (Boer et al., 2008; Kleine, Zwerenz, Zofel, & Shiratori, 2003). Many studies have tried to identify other CSF indicators of CNS infection in the postneurosurgical patient; few have been successful. CSF lactate has been shown to be highly sensitive and specific for bacterial infections after neurosurgical procedures. A level greater than 4.0 mmol/L predicts bacterial infection (Kleine et al., 2003; Leib et al., 1999; Wong & Poon, 2008).

#### Recommendations:

- CSF processing must be completed quickly to ensure accurate results because CSF is hypotonic. Cell counts decrease by 32% after 1 hour and 50% after 2 hours, and bacteria may not survive long periods in collection tubes (**Level 3**; Gray & Fedorko, 1992; Johnson & Sexton, 2009). For this reason, CSF is rapidly hand-delivered to the laboratory in some institutions. It is imperative that CSF obtained by lumbar puncture is not lost because the patient would require another lumbar puncture to obtain additional CSF.
  - After receiving the report of CSF analysis from the laboratory, notify the physician or advanced practice nurse immediately.
4. Treatment of infection
- The blood-brain barrier's tight junctions loosen with meningitis and this allows increased antimicrobial agent penetration. Ventriculitis may be more difficult to eradicate because bacteria remain as a source for seeding infection (Ziai & Lewin, 2009). Intraventricular administration of antibiotics has been advocated (van de Beek et al., 2010; Ziai & Lewin, 2009). No antibiotic has been approved for this route of administration by the FDA, and no drug dosing recommendations have been established.

#### Recommendations:

- The EVD should remain closed, usually for 1 hour, postinstillation of antibiotics (**Level 3**; van de Beek et al., 2010; Ziai & Lewin, 2009).
- Monitor patients receiving intraventricular antibiotic therapy for signs of neurotoxicity: meningeal irritation, delirium, confusion, focal to general seizures, and hearing loss (**Level 3**; James & Bradley, 2008; Ziai & Lewin, 2009).

- Infected EVD catheters should be removed, but there is no consensus on the removal timing (**Level 3**; James & Bradley, 2008; van de Beek et al., 2010; Ziai & Lewin, 2009). Unstable patient conditions may make catheter removal difficult. In multidrug-resistant acinetobacter meningitis there has been very high mortality when the EVD was not removed (**Level 2**; Guardado et al., 2008).

#### B. Noninfectious complication of EVD

1. Aneurysmal rebleeding and hemispheric shifts from reduction in ICP

The placement of an EVD for the relief of acute hydrocephalus in subarachnoid hemorrhage is the standard of care because the relief of the acute pressure improves the patient's clinical status, allowing the patient to then become a surgical or endovascular candidate (Fountas et al., 2006; Klopfenstein et al., 2004). Paradoxically, the EVD places the patient at risk for aneurysmal rebleeding by lowering the ICP. It is unknown why aneurysms rupture and how they stop bleeding but "pressure-compression" theories are the best answer to date (Fountas et al.). Sudden loss of CSF or decline in ICP increases the patient's risk for rebleeding. Fountas and colleagues' review of 10 studies found the relationship between EVD and rebleeding very difficult to quantify. Brawanski (2006) suggested that it would be unethical to try to obtain definite answers using a randomized clinical trial because some patients would not receive EVDs.

There is also a risk of hemispheric shifts from aggressive ICP management and CSF overdrainage in patients with large territorial hemispheric infarcts (Adams et al., 2007; Frank, 1995; Schwab, Aschoff, Spanger, Albert, & Hacke, 1996).

#### Recommendations:

- Monitor ICP drainage and ICP carefully in unsecured ruptured subarachnoid hemorrhage patients and maintain a low threshold to clamp the EVD to prevent CSF overdrainage (**Level 3**; Fountas et al., 2006).
- Rapid recognition of aneurysmal rebleeding can be life saving. Immediately notify the neurosurgical or neurointensivist team if bright red blood suddenly appears in the EVD tubing and drip chamber. There should be associated vital sign changes: elevated ICP and blood pressure. Discuss measures to control blood pressure elevations with the medical team (**Level 3**; Rose & Mayer, 2004), which may include

- continuous nicardipine infusion
- intravenous labetalol as needed.

- Care should also be taken to avoid CSF overdrainage in patients with unilateral mass lesions to avoid potential hemispheric shifts. (**Level 2**; Frank, 1995; **Level 3**; Adams et al., 2007).

## 2. CSF overdrainage

Overdrainage of CSF can result in CSF hypovolemia. The brain's descent may cause rupture of the bridging vessels and result in subdural hematoma formation (Paldino, Magilner, & Tenner, 2003). Pressure gradients caused by CSF drainage may lead to brain shift. Overdrainage of spinal fluid could result in lower pressure in the lumbar spine than in the brain. The lower spinal pressure and higher brain pressure may create a downward force that results in supratentorial herniation (Bloch & Regli, 2003; Pope, 1998). Overdrainage of CSF from an EVD can also create a pressure gradient. If the pressure in the lumbar spine is higher than in the brain, then upward force could result in upward transtentorial herniation. In cerebellar infarction or posterior fossa lesions and CSF drainage, upward herniation has been reported and is a concern (Adams et al., 2007; Kase & Wolf, 1993; Singha, Chatterjee, & Neema, 2009).

Overdrainage of CSF in patients with a hemicraniectomy resulting in paradoxical cerebral herniation has been reported (Fields, Landsberg, Skirboll, Kurien, & Wijman, 2006; Seinfeld, Sawyer, & Rabb, 2007). Subfalcine and transtentorial herniation occur when the pressure from CSF is inadequate to oppose the force of atmospheric pressure. If a patient with a deeply shrunken hemicraniectomy site experiences a mental status decline, herniation should be considered as a cause.

Treatments for CSF overdrainage resulting in mental status changes should focus on reversing the pressure gradients and increasing CSF volume. Trendelenberg position or supine is the first-line treatment (Field et al., 2006; Seinfeld et al., 2007).

Clinical symptoms that may indicate CSF overdrainage include

- postural headache that is relieved in the supine position. CSF hypovolemia results in loss of CSF buoyancy, which creates traction on the meninges and cerebral vessels (Miyazawa et al., 2003; Paldino et al., 2003). Elderly patients with smaller brain volumes develop less postural headaches (Miyazawa et al.).
- downward displacement of the brain may cause tension on or stretch the cranial nerves.

Cranial nerve palsies may develop from this traction (Bloch et al., 2003; Paldino et al., 2003).

- CN 8: hearing changes (hyperacusia) and vertigo
- CN 7: facial weakness
- CN 6: horizontal diplopia (lateral gaze produces double vision)
- CN 5: facial numbness
- mental status decline
- upward herniation could result in pressure on the midbrain with miotic or small pupils (Singha et al., 2009).

### Recommendations:

- The amount of CSF drainage can affect ICP (**Level 2**; Kerr, Weber, Sereika, Wilberger, & Marion, 2001). Raising the pressure level of the graduated burette above the zero reference level may create expected pressures within the brain.
  - A 20-cm pressure level above the zero reference level will usually result in an ICP of 20 mmHg. This pressure can have a "tamponade" effect on unsecured ruptured subarachnoid aneurysm (**Level 3**; Fountas et al., 2006). This can also be a method for gradual weaning from the EVD (**Level 2**; Klopfenstein et al., 2004).
  - A 10-cm pressure level above the zero reference level will usually result in normal pressures.
  - A zero pressure level is used for maximal pressure unloading and the pressure created from the CSF would be zero. In this case, there are usually other reasons the patient has higher pressures, such as cerebral edema.
- Maintain the EVD drip chamber at the prescribed zero reference and pressure levels (**Level 3**; Freiman & Spiegelberg, 2008; Woodward et al., 2002).
  - Inform the patient and his or her family that changing the bed position is to be performed only with assistance. Raising the level of the bed with an EVD at a fixed zero reference and pressure levels can result in a large increase in CSF drainage.
  - Ensure that the zero reference and pressure levels are maintained.
  - Educate all members of the medical team about the risks of changes in the height of the bed (**Level 3**; Muraskin, Roy, & Patrozza, 2007).
- Clamp the EVD any time there is a patient response or procedure that may cause CSF overdrainage (**Level 3**; Woodward et al., 2002). Unclamp and allow CSF drainage when the

stimulation has stopped and the patient is settled.

- Clamp EVD for coughing, vomiting, suctioning, or repositioning.
- Observe patient responses to provide care, and plan according to these responses.
- Sedation may be given prior to nursing procedures.
- Clamp the EVD prior to the disturbances that occur during patient transport. Unclamp when the nursing procedures are completed.

### 3. Hemorrhage and misplacement complications of EVD placement

EVD placement is one of the most common neurosurgical procedures, yet little data are found for hemorrhagic and misplacement complications. O'Neill, Velez, Braxton, Whiting, and Oh (2008) used data from the Nationwide Inpatient Survey to report that more than 20,000 EVDs are placed annually; this number is much larger worldwide. There has been no large prospective study to clarify the risks of hemorrhage and misplacement. Optimal placement of the EVD is in the ipsilateral lateral ventricle anterior to the foramen of Monro or into the top of the third ventricle but avoiding the choroid plexus in the bottom of the third ventricle. Optimal placement is achieved in 63%–77% of EVD placements (Huyette et al., 2008; Kakarla et al., 2008; Toma, Camp, Watkins, Grieve, & Kitchen, 2009). The right hemisphere, which is nondominant in 90% of the population, is the preferred site. Successful placement is verified by the free flow of CSF. Suboptimal placements can still provide a functional EVD and functional accuracy of 87% (Kakarla et al.). Patients with traumatic brain injury or midline shift are more challenging EVD placements and subject to less placement and functional accuracy (Kakarla et al.).

Intracranial hemorrhage can be a severe complication associated with the placement or removal of an EVD. No standard for quantifying the severity of hemorrhage is currently available. Clinically significant hemorrhages have been defined as those requiring surgical intervention or causing death. The rate of clinically significant hemorrhage has been reported to be 0.91%–1.2% for studies using CT scans (Binz, Toussiant, & Friedman, 2009; Kakarla et al.) Serious hemorrhage from EVD placement is a rare event, but other less serious hemorrhages occur at higher rates and the permanent effects of these are unknown (Binz et al.; Gardner, Engh, Atteberry, & Moossy, 2009).

Complication rates were similar for EVDs placed in the operating room and those placed in the intensive care unit (Gardner et al., 2009; Ngo et al., 2009). Catheter tract injury caused by multiple passes remained visible on follow-up radiologic studies (Huyette et al., 2008). Although these injuries may not result in clinical neurologic deficits, they may later result in neuropsychiatric issues for the patient.

#### Recommendations:

- The patient may need sedation, but this will vary greatly depending upon the medical condition of the patient: prior intubation, obtundation, or alert and awake. The nurse must monitor and document the patient's respiratory status and vital signs during the entire procedure and cannot leave the bedside. Other nurses will be required to assist if materials or medications are needed that are not present at the bedside.
- Assess CSF flow and ICP waveform (**Level 2**; Kakarla et al.).
- Prepare to assist with placement of an alternative ICP monitor if multiple freehand passes are needed (**Level 3**; Huyette et al., 2008).
- Postprocedure head CT scans are not routinely completed in all institutions, but patients often require a head CT for other reasons within 24–48 hours. Ensure that the head CT is completed in a timely fashion.

## XII. EVD removal

An EVD is a temporary solution or treatment for patients with increased ICP. An EVD is usually in place for 5–10 days. This time period gives the neurosurgery or neurointensivist team time to assess the cause and apply a more long-lasting solution or treatment. An EVD may be removed for the following reasons:

- ICP monitoring is no longer necessary
- infection risk is decreased
- ventriculoperitoneal shunt placement
- hydrocephalus resolution.

### A. EVD weaning

Raising and clamping the EVD prior to removal is essential to determine whether the device may be weaned. Only begin weaning if there is a written order with parameters set by the neurosurgeon or neurointensivist. Suggested weaning steps (**Level 1**; Varelas, 2006):

- Raise the drain height by 5 cmH<sub>2</sub>O every 12 hours only if ICP is not above the prescribed parameter.
- When the pressure level reaches 20 cmH<sub>2</sub>O and the EVD drains less than 200 mL/24 hours, clamp EVD (written order obtained by neurosurgery or neurointensivist team). It is

recommended to orient the stopcock “off” to drainage and “open” to the transducer. This technique is used to determine if the patient is continuing to tolerate weaning.

The ICP, pressure level, and the patient’s clinical status postclamping guide the neurosurgical or neurointensivist team’s decision to remove or unclamp the EVD.

#### B. Assisting with ventricular catheter removal

- Equipment:
  - sterile gloves
  - sterile suture removal materials
  - sterile dressing (i.e., sterile 4-in. x 4-in. gauze)
  - sterile specimen cup (if culture is ordered)
- Patient assessment:
  - neurological assessment
  - vital signs, ICP, CPP (**Level 3**; Varelas, 2006)
- Remove dressing; check for redness, edema, and CSF leak at insertion site (**Level 3**; Edgerton-Winn & Perry, 2006)
- Procedure:
  - Wash hands and wear a mask with eye shield or goggles and sterile gloves.
  - Assist the physician or advanced practice nurse as needed with removal of the catheter.
  - Apply a sterile occlusive dressing.
  - Discard used supplies and wash hands.

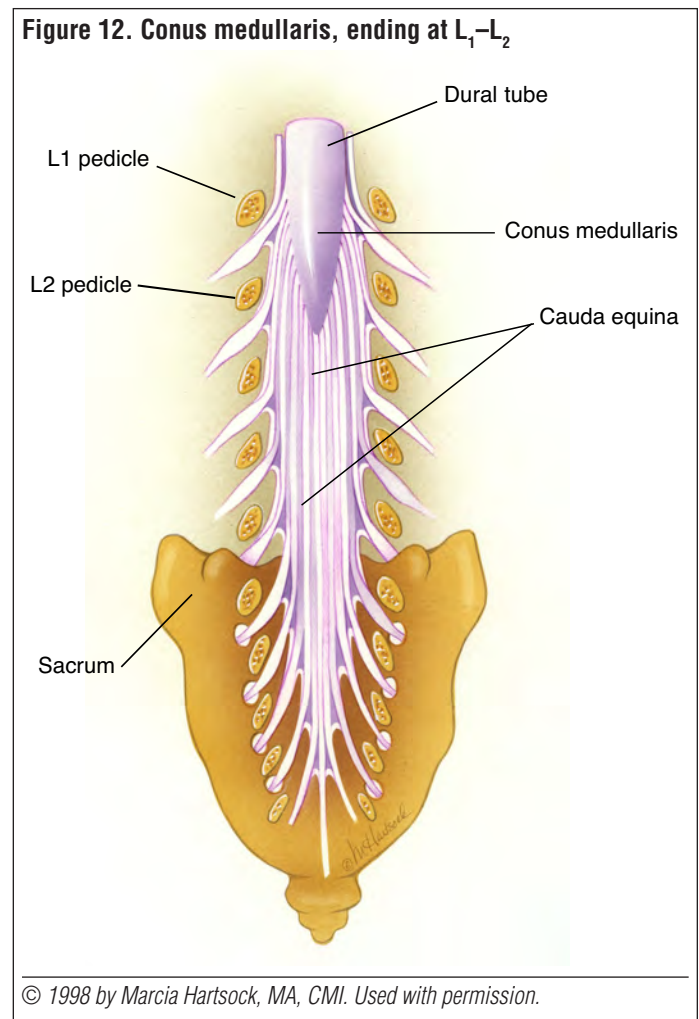
### XIII. Patient and family education

- Explain the need and reason for maintaining the head-of-bed position to maintain accuracy and safety of treatment.
- Explain the processes of draining fluid and opening the stopcock hourly and the reason for lowering and raising the drainage device during treatment of ICP monitoring or EVD.
- Explain the effects of environment, care, and external stimuli on the patient’s ICP as indicated. Involve the family in plans to control stimuli to minimize elevation of ICP readings.
- Assess the patient’s and family’s understanding of intraventricular catheter removal. Explanations for specific needs may allay fears (**Level 3**; Alexander, Galleck, Presciutti, & Zrelak, 2007).
- Explain the intraventricular catheter removal procedure. Review normal parameters and patient care postremoval. An explanation of expected interventions may allay the patient’s and family’s anxieties, encourage questions, and promote therapeutic family interaction.
- Treat patients’ pain and anxiety with appropriate medication that will be safely tolerated

and does not alter neurological status (**Level 3**; Walker, 2007).

### XIV. Lumbar drainage devices

Lumbar drainage devices (LDDs) are closed sterile systems that allow the drainage of CSF from the subarachnoid space. LDDs are inserted via a specialized spinal needle, known as a Touhy needle, into the lumbar subarachnoid space at the L<sub>2</sub>–L<sub>3</sub> level or below, thus avoiding injury to the spinal cord, which ends at the conus medullaris at the L<sub>1</sub>–L<sub>2</sub> vertebral bodies (**Figure 12**; Willschke et al., 2007). In the lumbar CSF space, the flexible spinal catheter will be alongside the cauda equina, which consists of the ventral and dorsal spinal nerve roots that descend from the spinal cord and exit the spinal canal at lumbosacral levels (Whedon & Glassey, 2009). Insertion of the spinal catheter may cause transient radicular pain if the catheter brushes against one of the spinal nerve roots. Occasionally, the pain can be persistent, especially if lumbar spinal stenosis causes the spinal catheter and the spinal nerve roots to remain in close contact.



## XV. Indications for LDD placement

Placement of an LDD is an accepted medical therapy for the treatment of postoperative or traumatic dural fistulae, such as a CSF leak (Sade, Mohr, & Frenkiel, 2006; van Aken et al., 2004; Vourc'h, 1963), treatment of shunt infections (Pudenz, 1989; Thompson, 2000), and for the diagnostic evaluation of idiopathic normal pressure hydrocephalus (Marmarou, Bergsneider, Klinge, Relkin, & Black, 2005). LDDs also are used to reduce ICP during a craniotomy (Grady et al., 1999; Samadani, Huang, Baranov, Zager, & Grady, 2003) and as adjuvant therapy in the management of traumatically brain-injured patients (Munch, Bauhuf, Horn, Roth, & Schmiedek, 2001).

Additional indications for LDDs include treatment of patients with thoracoabdominal aortic aneurysms (thoraco-AAA) to improve spinal cord perfusion (Bethel, 1999; Coselli, LeMaire, Schmittling, & Koksoy, 2000; Crawford et al., 1991; Safi et al., 1994; Safi et al., 1996), to manage nontraumatic subarachnoid hemorrhage to prevent vasospasm (Klimo, Kestle, MacDonald, & Schmidt, 2004), and to manage increased ICP associated with cryptococcal meningitis (Macswen et al., 2005). Although the use of LDDs for these additional indications has been reported in the literature, they have been used in only a limited number of studies.

### A. Relative contraindications (Adler, Comi, & Walker, 2001; Howard et al., 2000)

- Coagulopathy, active bleeding, or severe thrombocytopenia
- Brain abscess
- History of prior lumbar spine surgery
- History of prior lumbar vertebral fracture

### B. Absolute contraindications (Joffe, 2007)

- Increased ICP (excludes documented pseudotumor cerebri patients)
- Unequal pressures between the supratentorial and infratentorial compartments as evidence by the following head CT findings:
  - midline shift
  - loss of suprachiasmatic and basilar cisterns
  - posterior fossa mass
  - loss of the superior cerebellar cistern
  - loss of the quadrigeminal plate cistern
- Infected skin over the needle entry site
- Spinal epidural abscess
- Intracranial mass
- Obstructive noncommunicating hydrocephalus
- Spinal arteriovenous malformation

## XVI. LDD equipment setup

### A. Equipment needed

In preparation for insertion, the nurse should gather the following equipment (Note: Many disposable LDD kits contain standard supplies. The

provider should check the kit's contents before beginning the procedure.):

- antimicrobial scrub solution (povidone-iodine)
- antimicrobial swabs or swab sticks (povidone-iodine)
- sterile gloves, surgical caps, masks, sterile surgical gown
- sterile srape
- local anesthetic (preservative-free 1% lidocaine HCl)
- 5- to 10-cc syringe with 23-gauge needle for lidocaine administration
- small-gauge atraumatic spinal needle (Thomas, Jamieson, & Muir, 2000; Vallejo, Mandell, Sabo, & Ramanatham, 2009)
- lumbar drainage catheter
- 3–4 sterile tubes for CSF sampling
- sterile scissors and a needle holder (wound closure kit)
- sterile suture with needle
- sterile occlusive dressing
- sterile CSF drainage system (tubing, collection bag)
- sterile, preservative-free saline (0.9%) in a 30- or 40-mL syringe to flush drainage system
- system holder (device to secure system to pole to maintain ordered level)
- procedure tray (to hold supplies).

### B. Priming the lumbar drainage system

The LDDs arrive from the manufacturer with all stopcocks in the “neutral” position. Variations in transducer placement on the device will determine positioning of the “off” marker on the stopcocks.

The drainage device should be primed with sterile, preservative-free normal saline (0.9%). (**Level 3**; Littlejohns & Trimble, 2005). The drainage device should be secured to an IV pole at the patient's bedside. The device may be hung on an IV pole using the cord attachment or secured with a pole clamp and the cord attachment. For patient safety, priming the device should be accomplished by attaching a 30-mL (or smaller) syringe filled with sterile preservative-free normal saline to the patient line stopcock using sterile procedure (**Level 3**; Tanner et al., 2006).

Manufacturers of lumbar drainage systems recommend priming the system prior to attaching the system to the patient's catheter. Failure to prime the tubing results in variable speeds of CSF flow as it travels through the tubing and the risk that air bubbles will collect and also change the flow of fluid from the patient to the collection bag (Littlejohns & Trimble).

### Procedure for priming the LD tubing:

- Using a sterile procedure, attach the syringe to the patient line stopcock (distal aspect of tubing; Tanner et al., 2006).
- Rotate the stopcock position “off” toward the drainage device.
- Slowly inject the sterile preservative-free saline toward the distal aspect (patient end) of the tubing. When the fluid has reached the distal end of the tubing, allow several drops of fluid to exit the end of the tubing to ensure there are no air bubbles in the tubing. Note: Many systems do not require that the end cap be removed to prime the tubing. Please check with manufacturer.
- Keeping the syringe in place, rotate the stopcock “off” to the distal aspect of tubing. Ensure that the panel mount stopcock is open to the graduated burette.
- After priming, the stopcock on the distal patient line should remain “off” to the distal aspect to ensure no fluid leaks from the system prior to the physician or advanced practice nurse connecting the drainage device.
- The drainage device and the catheter from the patient are connected by the qualified healthcare provider using sterile procedure.
- Set the zero reference level. Raise or lower the system to the appropriate anatomical landmark. This should correspond to the zero reference mark on the drainage system device.

Although it is widely accepted that EVDs have a common anatomical zero reference point, practice varies with LDs. The literature does not currently support one anatomical zero reference point for LDs. The zero reference point should be prescribed by the healthcare provider.

Some LD systems use a laser-leveling device to provide the nurse with a rapid means to level the system. Other leveling tools include carpenter or string levels. Use caution to ensure the laser light does not shine into the patient’s eyes or the eyes of other staff or visitors who may be present in the room. If the laser-leveling device includes a bubble level, ensure the bubble is within the markings to position the system correctly.

**Recommendation:** Set the zero reference level with each patient position change, particularly when the head of the bed has been raised or lowered, during patient transport, or if the patient has been out of bed or is returned to bed (Level 3, expert panel consensus).

#### C. Set pressure level

The pressure level on the graduated burette is prescribed by the physician or advanced practice nurse. The pressure level on the graduated burette,

is prescribed by the qualified healthcare provider. When the pressure in the lumbar space is higher than the prescribed pressure level, CSF will drain into the graduated burette. Hydrostatic pressure dictates drainage of CSF. The fluid column pressure must be greater than the weight of the CSF in the system before drainage occurs.

#### D. Draining CSF from an LDD

Turn the panel mount stopcock “open” to the graduated burette to continuously drain CSF. CSF drainage may be managed by two different techniques, both of which require a qualified healthcare provider order:

- continuously draining CSF to achieve a prescribed amount (usually 5, 10, or 15 mL/hour)
- intermittently draining CSF by opening the stopcock once an hour, draining a prescribed amount, then positioning the stopcock “off” to drainage.

## XVII. LDD insertion

### A. Location for performing procedure

Individual institutional policies dictate where the LDD placement procedure may be performed and the hospital location for ongoing patient monitoring while the LDD is in place.

### B. Preplacement provider evaluation

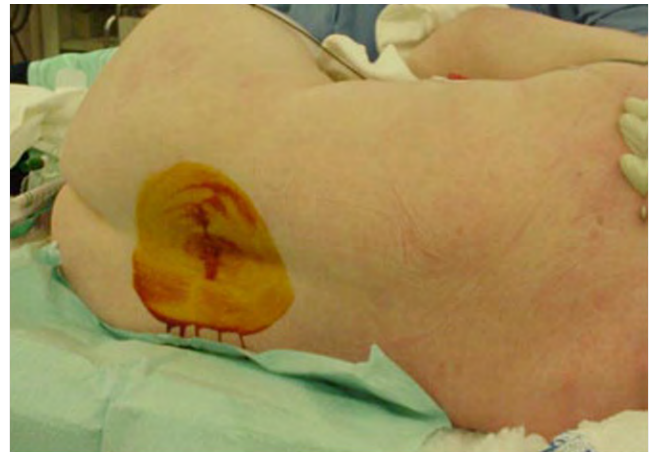1. Subjective data gathering
  - a. History and review of symptoms relevant to the presenting complaint or procedure to be performed
    - Headache
    - Confusion
    - CSF leak
    - Altered mental status
    - Nuchal rigidity
    - Fever
    - Bleeding or bleeding disorder
    - Lower extremity sensory deficits
    - Lower extremity weakness and limitations in ambulation
    - Back pain
  - b. History of prior back surgery
  - c. History of prior lumbar puncture or drain placement
  - d. History of liver dysfunction due to bleeding risk
  - e. History of seizures
  - f. History of cerebral bleeding, stroke, or traumatic brain injury
  - g. History of bowel or bladder incontinence or retention (due to possible nerve irritation from LDD)
2. Objective data gathering

- Physical examination appropriate to the procedure being performed
- Vital signs
- Pain evaluation
- Neurological examination
- Mental status
- Sensory examination
- Motor examination
- Evaluation for nuchal rigidity
- Evaluation for papilledema
- Skin evaluation at site of insertion
- Presence of scars or incisions
- Signs and symptoms of skin infection
- Review of laboratory data
- Review of radiographic studies
- Indications for head CT prior to procedure (Hasbun, Abrahams, Jekel, & Quagliarello, 2001) include patients
  - 60 years of age and older
  - who are immunocompromised
  - with known CNS lesion
  - who have had a seizure within 1 week of presentation
  - with abnormal level of consciousness
  - with focal findings on neurological examination
  - with papilledema seen on physical exam with clinical suspicion of elevated ICP

#### C. Prepare patient for LDD catheter insertion

1. Ensure informed consent is obtained from the patient or appropriate legal designee. Note: Discussion must include rationale for placement, risks and benefits of the procedure, and a review of procedural steps. Patient instruction should also include staff notification prior to changing the head of bed position or development of headache, numbness, tingling, or weakness in the extremities.
2. Complete a “time out” with all the required steps.
3. The most crucial step for successful LDD placement is patient positioning. The lateral decubitus position (side-lying) may be used: firm bed, head on pillow, head flexed with chin on the chest, legs maximally flexed toward the head (**Figure 13**). An alternate position is to have the patient sitting upright, flexed forward, and supported by a stable table or assistant (**Level 2**; Abe, Yamamoto, Itoman, Nakasone, & Kanayama, 2005; Byers, O’Malley, Alli, & Dominici, 2006; Fernandez et al., 2010; Thundiyil, O’Brien, & Papa, 2007).

**Figure 13. Patient positioning for LDD insertion**



© Copyright 2007 by Karen March. Reprinted with permission.

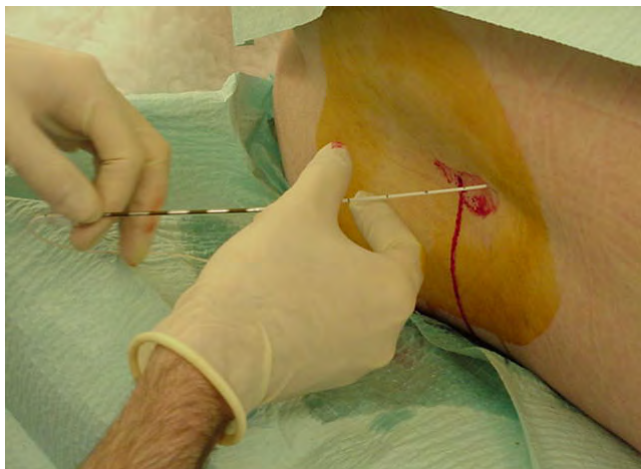
#### D. LDD insertion

The qualified healthcare provider, which may include advanced practice nurses in some settings, inserts the LDD catheter using the following procedure:

1. Wash hands.
2. Identify interspaces and mark the puncture site at the L<sub>4</sub>–L<sub>5</sub> interspaces in a perpendicular line from the iliac crest (Ferre, Sweeney, & Strout, 2009; Sandoval, Shestak, Sturmman, & Hsu, 2004).
3. Wear sterile gloves to set up equipment (lumbar tray).
4. Prepare the skin with providone-iodine. Begin at the site marked for the needle puncture, working outward in circular motion, and repeat twice (Calfee & Farr, 2002). Note: Use of 2% chlorhexidine for preparation is controversial. Its use is recommended for skin antisepsis prior to neuroaxial blocks (spinal and epidurals) by the American Society of Regional Anesthesia and Pain Medicine and by the American Society of Anesthesiologists. However, both the FDA and package insert warn against its use in preparation for lumbar puncture or if in contact with meninges (**Level 3**; Crosby, 2008; Dailey, 2009).
5. Allow adequate time for skin preparation to dry (2 minutes).
6. Drape the patient with sterile drape(s).
7. Recheck the landmarks.
8. Infiltrate the skin and subcutaneous tissue with preservative-free 1% lidocaine with a 23-gauge needle.
9. Insert the Touhy needle into the midline of the interspace with bevel up. Direct the

- needle on a 10-degree angle toward the umbilicus (horizontal axis; **Level 3**; Abe et al., 2005; O'Connor, Gingrich, & Moffat, 2007; Williams, Lye, & Umapathi, 2008)
10. Advance the needle slowly, removing the stylet every 2–3 millimeters to check for CSF flow. Note: If the patient complains of nerve root pain, do not advance the needle. Remove stylet and check for CSF. If none, then replace the stylet and remove. Remove the needle to subcutaneous tissue, change angle, and continue. If bony resistance is noted, discard the needle and replace it. If blood is returned, watch for clearing of fluid; if there is no clearing, replace the stylet and remove the needle.
  11. After CSF flow is established, rotate the needle 90 degrees counter-clockwise (bevel in transverse plane).
  12. Remove 1–2 cc of CSF for each of 3–4 tubes and send samples to the laboratory for glucose, protein, cell count, gram stain, culture, and cytology, as indicated.
  13. Thread the lumbar drainage catheter into the subarachnoid space. Withdraw the needle and attach it to an epidural drainage system (**Figure 14**).

**Figure 14. Lumbar drain catheter insertion**



© Copyright 2007 by Karen March. Reprinted with permission.

14. Ensure drain patency. Correct with catheter manipulation as necessary.
15. Secure the 3-way stopcock with a suture tie, connecting the spinal catheter and the external drainage system.
16. Cover the catheter insertion site with a sterile transparent occlusive dressing. Ensure that there are no kinks in the drainage system beneath the dressing. Document

the date and time of placement on the dressing.

17. Ensure the catheter is secured to the patient.
  18. Assist the patient into a more comfortable position (**Level 3**; Ellenby, Tegtmeyer, Lai, & Braner, 2006; Straus, Thorpe, Holroyd-Leduc, 2006). Note: Postprocedure bed rest or IV-fluid hydration is not indicated following placement of an LDD (**Level 3**; Sudlow, & Warlow, 2009; Thoennissen et al., 2001).
- E. Potential procedural complications (Evans, Armon, Frohman, & Goodin, 2000; Coplin, Avellino, Kim, Winn, & Grady, 1999; Forsythe, Gupta, & Cohen, 2009; Governale, Fein, Logsdon, & Black, 2008; Grady et al., 1999; Horlocker, Abel, Messick, & Schroeder, 2003; Miglis, & Levine, 2010)
- Postdural puncture headache
  - Lumbar sacral nerve injury or paresthesias
    - Needle-related neural trauma
    - Local anesthetic toxicity
  - Spinal cord ischemia
  - Cerebrospinal fluid leak
  - Meningitis
  - Insertion site infection
  - Spinal or epidural hematoma
  - Catheter fracture or catheter retention
  - Subdural hematoma or subarachnoid hemorrhage
  - Cerebral herniation
  - Cerebral venous thrombosis
  - Cerebral spinal fluid hypovolemia
- F. Documentation
1. The provider performing the procedure must record the following: pre-examination physical findings, indications for and details of the procedure, consent, time out, medications administered, patient tolerance, any complications noted, patient teaching or instruction, and a postprocedure physical examination.
  2. The nurse assisting in the procedure should document the name of the practitioner who placed the LDD, as well as the date and time of the drain insertion. Assess and document color, clarity, and volume of initial CSF drainage. Record the condition of the insertion site, initial dressing, and patency of the drainage system.

### XVIII. Nursing responsibilities postplacement

In general practice, the registered nurse should minimize handling of drainage device as much as possible to prevent infection. Hand hygiene and use of gloves are

recommended whenever the LDD is handled (**Level 2**; O’Grady et al., 2011; Leverstein-van Hall et al., 2010).

### Recommendations:

#### A. Patient assessment

1. The patient should be assessed every hour in the ICU setting and every 1–2 hours in the intermediate care or floor setting (**Level 3**, expert panel consensus). Changes from the baseline neurological assessment include, but are not limited to, decreased level of consciousness, focal deficit, pupillary changes, vision, headache, and signs of meningeal irritation (e.g., photophobia, nuchal rigidity, headache, irritability). More frequent assessment may be indicated by patient condition or type of drainage regulation used. The physician, advanced practice nurse, or other qualified healthcare provider should be notified immediately of all neurological changes.
2. The patient should be assessed every 1–2 hours (Q 1 hour for intensive care unit setting; Q 2 hours for floor setting) for signs and symptoms of infection, including presence of elevated temperature and signs of infection or leaking at the insertion site (**Level 2**; Clevenger, 1990; Governale et al., 2008; Hoekema, Schmidt, & Ross, 2007).
3. The amount, clarity, and color of CSF drainage should be assessed and recorded every 1–2 hours (1 hour for ICU setting; 2 hours for floor setting) as ordered by the physician, advanced practice nurse, or other qualified healthcare provider. More frequent checks may be required while ensuring the level of the drain is yielding appropriate amounts of CSF drainage for volume-regulated drainage. During this time, the level of the drain and security of the drainage system to maintain the appropriate position should also be assessed (**Level 3**; expert panel consensus).

#### B. Patient care

1. Patient positioning is crucial to prevent complications from lumbar drainage. The head of the bed, height of drainage chamber, and changes in patient positioning must be monitored closely to prevent sudden overdrainage.
2. Patients may turn from side to side without significant impact on drainage unless the catheter is found to be positional. Nursing staff should monitor which positions result in variances in drainage rate from the LDD and plan patient care and

positioning accordingly (**Level 2**; Açıkbaş, Akyüz, Kazan, & Tuncer, 2002; Macsween et al., 2005; Thompson, 2000).

3. Use of lockouts on the height of the bed and the head-of-bed elevation to prevent self-positioning is necessary for patients with cognitive impairments and a safety intervention for all patients. Patients with cognitive symptoms will also require an observer at the bedside or restraints to prevent complication from lumbar drainage (**Level 3**; Clevenger, 1990; Governale et al., 2008; Thompson, 2000).
  4. While making changes to the patient’s positioning, the LDD should be clamped so that overdrainage does not occur. After the patient is positioned in the desired position, the LDD should be leveled and the orientation of stopcocks should be evaluated to ensure they are allowing drainage per physician, advanced practice nurse, or other qualified healthcare provider order (**Level 2**; Clevenger, 1990; Macsween et al., 2005; Thompson, 2000).
  5. Instruct patients to avoid coughing, sneezing, and straining whenever possible to avoid overdrainage from increased thoracic pressure levels (**Level 3**; Thompson, 2000).
  6. Education must be provided to the patient and family regarding the restrictions to patient positioning and symptoms of complications. Instruct patients and their families to contact the nurse when any neurological changes, headache, or disruption to the drainage system occur, or to call for assistance to make position changes that might affect the amount of drainage (**Level 3**; Clevenger, 1999; Macsween et al., 2005).
  7. Effective communication to all healthcare members that an LDD is in place with a review of restrictions is critical to the patient’s safety. Some organizations utilize signs posted on the wall at the head of the patient’s bed to alert healthcare members to restrictions.
- #### C. System maintenance
- Insufficient data exist to specifically recommend type of dressing for LDDs and the frequency of dressing changes. Therefore, many of the interventions recommended by the Centers for Disease Control and Prevention to reduce infection of intravascular catheters are widely accepted for LDDs as well.
  - The dressing must be sterile.
  - It is easier to visualize the insertion site for

signs of infection when a transparent dressing is in place (**Level 2**; O’Grady et al., 2011; Thompson, 2000).

- Dressings should remain clean, dry, and intact. The dressing should be changed if wet or soiled (**Level 2**; O’Grady et al., 2011; Thompson, 2000).
  - Transparent dressings may stay in place as long as they are clean, dry, and intact. Gauze dressings must be changed more frequently (O’Grady et al., 2011).
  - If drainage is noted on the dressing, the prescriber should be notified immediately of potential CSF leak at the insertion site.
1. Drainage system
    - The drainage system must be securely fastened to a location that will not cause pressure to be placed on the tubing with minor position changes or allow the drainage unit to fall and cause sudden overdrainage.
    - All connections in the drainage system and tubing should be tight. All ports should have a closed cap or luer lock adaptor to prevent leakage and decrease the possibility of infection.
    - The use of intravenous infusion pumps to control the flow of CSF has been reported in the literature (Houle et al., 2000; Vender, Houle, Flannery, Fryburg, & Lee, 2000); however, this is considered off-label use and is not recommended.
  2. Changing the drainage bag
    - It is recommended to change the drainage bag when  $\frac{3}{4}$  full (**Level 2**; Leverstein-van Hall et al., 2010; Thompson, 2000).
    - Perform hand hygiene and wear gloves prior to handling the LDD (**Level 2**; O’Grady et al., 2011; Leverstein-van Hall et al., 2010; Thompson, 2000).
    - Orient stopcock on drainage system to stop CSF flow from the patient.
    - Disconnect the bag from the system using strict aseptic technique (**Level 2**; O’Grady et al., 2011; Thompson, 2000).
    - Place cap over exposed port on the  $\frac{3}{4}$ -full bag.
    - Connect replacement drainage bag to the LDD system utilizing strict aseptic technique (**Level 2**; O’Grady et al., 2011; Thompson, 2000).
    - Ensure connections are tight and that the stopcocks and clamps are in the correct position to allow drainage regulation per qualified healthcare provider’s order.

#### D. Documentation

Assessments and interventions regarding drain care and manipulation should be documented as they occur. A thorough baseline neurological assessment should be documented prior to drain insertion for comparison. Color, clarity, and amount of drainage should be documented upon each assessment (Q1 hour for ICU setting; Q2 hours for floor setting; **Level 3**, expert panel consensus).

### XIX. LDD troubleshooting

#### A. Break in the sterile system

1. Consider the system no longer sterile if disconnection occurs.
2. Turn the stopcock closest to the patient “off” to the patient or clamp the catheter to close off the system. Notify the healthcare provider immediately.
3. Prepare replacement system (see procedure for priming the LDD).

#### B. Occlusion of tubing

1. Blockage of the catheter due to blood or debris may occur in 5%–33% of patients (Ganjoo, 2009).
2. If blockage is located proximal to the patient, notify the physician.
3. If blockage is located past the port nearest the patient, consider flushing the system through the first port to the occlusion or as per facility policy (i.e., in some facilities this is performed by staff nurses and in other facilities this is performed only by advanced practice nurses and physicians).
  - Use of preservative-free saline is required.
  - Turn the stopcock “off” to the patient prior to flushing to prevent backflow of CSF. Only flush the system from the direction of the patient toward and into the drainage collection bag.
  - Aseptic technique should be used, including sterile gloves, mask, and 3-minute preparation of the port.
  - Do not attempt to withdraw the blockage or milk the tubing to remove the blockage.

#### C. No CSF drainage in collection chamber

1. Assess CSF flow through the drainage system.
  - You may lower the drain briefly to assess flow into the drip chamber.
  - Assess the integrity of the drainage system. Check for drainage at the insertion site, position stopcocks “open” to the drain, and ensure the catheter is not kinked at injection site and that there are no disconnections.

- Notify the physician or advanced practice nurse of the above assessment.
- **It may be necessary to flush the system;** follow facility guidelines (**Level 3**; Wiegand & Carlson, 2005).

#### D. Excessive CSF drainage

- The system should be set at the correct zero reference level in relation to the patient landmark. If draining for a specific volume, raise the collection system and reassess the drainage rate.
- Monitor the patient's neurologic examination and report any changes.
- Notify the physician if excessive drainage persists or if neurologic change occurs.
- Sudden onset or worsening of headache should alert the nurse to assess for excessive CSF drainage (**Level 3**; Littlejohns, 2009).
- Position changes of the drain or patient can change the amount of CSF drainage (**Level 3**; Overstreet, 2003).
- Mild symptoms include transient headaches, nausea, and vomiting. Analgesics and antiemetics are usually sufficient for treatment (**Level 3**; Ganjoo et al., 2009).
- Overdrainage of CSF may result in tension pneumocranium, central herniation, or subdural hematoma by causing a collapse of the ventricles and increased negative pressure leading to rupture of veins in the dura (**Level 3**; Littlejohns, 2009).

## XX. Management of LDD complications

### A. Bacterial colonization and infection

- The frequency of colonization and infection increases every time the system is opened, irrigations are performed, or the LDD is left in place for more than 5 days.
- Usual duration of catheter dwell time is 5–10 days (Littlejohns, 2009).
- Local site infections can occur at a rate of 0.8% (Governale et al., 2008).
- Symptoms include fever, redness, swelling, drainage, or pain at the insertion site.

#### Recommendation:

- **Remove the drain and provide antibiotic treatment (Level 3; Governale et al., 2008).**

### B. Meningeal irritation

- Meningitis can have an incidence of 2%–10% with gravity-dependent continuous drainage (Ganjoo et al., 2009).
- Symptoms include nuchal rigidity, headache, nausea, vomiting, photophobia, and decreased level of consciousness.

- Monitor closely for early signs of infection: fever and elevated WBC.

#### Recommendation:

- Monitor for nuchal rigidity, photophobia, and turbid or purulent CSF. The physician should be notified immediately of these symptoms (**Level 3**; Littlejohns, 2009).

### C. Nerve root irritation

- Transient lumbar nerve root irritation has been described in 14% of patients in one report (Ganjoo et al., 2009) and 2.6% in another (Governale et al., 2008).
- Irritation may be due to catheter positioning.
- Symptoms include radicular leg pain, numbness and tingling, and changes in deep tendon reflexes.
- Notify the healthcare provider immediately. The healthcare provider may order a change in position, withdraw or remove the catheter, and order analgesics.

#### Recommendation:

Prompt catheter removal by the healthcare provider is recommended for limb weakness (**Level 3**; Ganjoo et al., 2009).

### D. Tension pneumocranium

- Excessive and rapid drainage of CSF can lead to simultaneous siphoning in of air through fistulas that are communicating with air sinuses (Ganjoo et al., 2009).
- This is a life-threatening situation and requires immediate drain clamping and notification of the physician (Ganjoo et al., 2009).
- Symptoms include a sudden decreased level of consciousness and focal neurologic deficit such as unilateral weakness (Thompson, 2000).
- Treatment includes occlusion of drainage tube, placing the patient in supine position, high flow O<sub>2</sub> (100%) per physician order, and performing ongoing assessment.

### E. Herniation

- **Inadequate drainage of CSF may result in increased intracranial pressure and downward shift of intracranial contents.**
- **Symptoms include decreased level of consciousness, irritability, and change in neurological status (i.e., paresis, abnormal breathing pattern, change in pupil size and reactivity).**
- **Treatment includes occlusion of drain, hyperventilation, and lowering of the head of the bed per physician order.**

### F. Subdural hemorrhage

- **Overdrainage of CSF can cause ventricle collapse and increased negative pressure leading to rupture of veins, which can lead to**

subdural hematoma (Littlejohns, 2009). Occurrence of 1.3% has been described (Governale et al., 2009).

- Observe for changes to neurological status and call the healthcare provider immediately.
  - **Symptoms include change in level of consciousness and change in neurological examination and bloody drainage in the system.**
  - Treatment includes notifying the healthcare provider, occlusion of drain per physician order, and continued monitoring of the patient.
- G. Intradural hematoma
- Intradural hematoma has been reported as a complication at the insertion site of LD catheters in thoracic abdominal aortic aneurysm repair (incidence rate 3.2%; Weaver et al. 2001). It may occur following drain removal.
  - **Symptoms include progressive lower extremity weakness, loss of reflexes, and decreased muscle tone.**
  - Treatment includes immediate notification of healthcare provider and ongoing assessment.
- H. Retained catheter
- **Reported at 0.4% during placement (Governale et al., 2009)**
  - Assess for intact catheter tip upon removal and report immediately to physician if catheter tip is not intact.
- I. Intracranial venous thrombosis
- Craniospinal elasticity is altered when the dura is injured. Acute venous dilation can lead to venous stasis and thrombosis (Miglis & Levine, 2010).
  - Symptoms include postprocedural headache that intensifies or persists for longer than a week and neurologic change.
  - **Treatment in adults includes venous ultrasound and anticoagulation; consider placement of inferior vena cava filter.**
  - Treatment options in children differ from the adult population. Computer tomography (CT) angiography is performed for diagnosis and hydration is the first-line treatment. The use of anticoagulant therapy is not preferred; inferior vena cava filters are rarely used in the pediatric population.

#### **XXI. LDD removal—nursing responsibilities**

Assist with removal of an LDD (**Level 3**; Wiegand & Carlson, 2005).

- Prepare equipment: sterile gloves, sterile suture removal kit, sterile hemostat, and new dressing supplies.
- Wash hands and apply protective eye gear and mask.
- Assist the physician or designee with removal of the catheter. Culture the tip as ordered by physician, advanced practice nurse, or other qualified healthcare provider.
- Apply a sterile occlusive dressing.
- Assess for neurologic change in the patient.
- Discard used equipment and wash hands.

#### **XXI. Patient and family education**

- A. Teach the patient and family the rationale for drain placement, function, and potential adverse symptoms (headache, mild discomfort at insertion site; **Level 3**; Overstreet, 2003).
- B. Teach the patient to avoid sneezing, coughing, and straining (**Level 3**; Thompson, 2000).
- C. Inform patient that bed control (height, head) will be locked to reduce risk of overdrainage and potential adverse effects (**Level 3**; Governale, 2008).
- D. Explain the need to notify the nurse for
- change in position to reduce the risk of overdrainage, fractured catheters, or disconnection (**Level 3**; Governale et al., 2008)
  - change in or new onset of physical signs or symptoms, such as headache, leg paresthesia, and saturated dressing at catheter site
  - an equipment disconnection.
- E. If the patient is unable to follow directions, physical or chemical restraint or close observation by staff or family may be necessary (**Level 3**; Littlejohns, 2009; **Level 3**; Governale et al., 2008).

## References

- Abe, K. K., Yamamoto, L. G., Itoman, E. M., Nakasone, T. A. F., & Kanayama, S. K. (2005). Lumbar puncture needle length determination. *American Journal of Emergency Medicine*, 23, 742–746.
- Açikbas, S. C., Akyüz, M., Kazan, S., & Tuncer, R. (2002). Complications of closed continuous lumbar drainage of cerebrospinal fluid. *Acta Neurochirurgica*, 144, 475–480.
- Adams, H. P., de Zoppo, G., Alberts, M. J., Bhatt, D. L., Brass, L., Furlan, A. et al. (2007). Guidelines for the early management of adults with ischemic stroke: a guideline from the American Heart Association/American Stroke Association Stroke Council, Clinical Cardiology Council, Cardiovascular Radiology and Intervention Council, and the Atherosclerotic Peripheral Vascular Disease and Quality of Care Outcomes in Research Interdisciplinary Working Groups: The American Academy of Neurology affirms the value of this guideline as an educational tool for neurologists. *Stroke*, 38, 1655–1711.
- Adler, M. D., Comi, A. E., & Walker, A. R. (2001). Acute hemorrhagic complication of diagnostic lumbar puncture. *Pediatric Emergency Care*, 17(32), 184–188.
- Alexander, S., Galleck, M., Presciutti, M., & Zrelak, P. (2007). *Guidelines for clinical practice: Care of the patient with aneurysmal subarachnoid*. Glenview, IL: American Association of Neuroscience Nurses.
- Arabi, Y., Memish, Z., Balkhy, H., Francis, C., Ferayan, A., Shimemeri, A., et al. (2005). Ventriculostomy-associated infections: Incidence and risk factors. *American Journal of Infection Control*, 33, 137–43.
- Arbour, R. (2004). Intracranial hypertension: Monitoring and nursing assessment. *Critical Care Nurse*, 24 (5), 19–32.
- Association of periOperative Registered Nurses. (2009). *Perioperative standards and recommended practices*. Denver, CO: Author.
- Bader, M. K., Littlejohns, L., & Palmer, S. (1995). Ventriculostomy and intracranial pressure monitoring: In search of a 0% infection rate. *Heart & Lung*, 24, 166–172.
- Barker, E. (2008). *Neuroscience nursing: A spectrum of care* (3rd ed.). St. Louis, MO: Mosby Elsevier.
- Bauer, D. F., McGwin, G., Melton, S., George, R., & Markert, J. M. (2011). The relationship between INR and development of hemorrhage with placement of ventriculostomy. *Journal of Trauma-Infection & Critical Care*, 70(5), 1112–1117.
- Beer, R., Lackner, P., Pfausler, B., & Schmutzhard, E. (2008). Nosocomial ventriculitis and meningitis in neurocritical care patients. *Journal of Neurology*, 255, 1617–1624.
- Beer, R., Pfausler, B., & Schmutzhard, E. (2009). Management of nosocomial external ventricular drain-related ventriculomeningitis. *Neurocritical Care*, 10, 363–367.
- Bethel, S. A. (1999). Use of lumbar cerebrospinal fluid drainage in thoracoabdominal aortic aneurysm repairs. *Journal of Vascular Nursing*, 3, 53–58.
- Binz, D. D., Toussiant III, L. G., & Friedman, J. A. (2009). Hemorrhagic complications of ventriculostomy placement: A meta-analysis. *Neurocritical Care*, 10, 253–256.
- Bloch, J., & Regli, L. (2003). Brain stem and cerebellar dysfunction after lumbar spinal fluid drainage: Case report. *Journal of Neurology, Neurosurgery and Psychiatry*, 74, 992–994.
- Boeer, K., Siegmund, R., Pfister, W., Isenmann, S., & Deufel, T. (2008). Correction of ventricular cerebrospinal fluid (CSF) samples for blood content does not increase sensitivity and specificity for the detection of CSF infection. *Clinical Chemistry and Laboratory Medicine*, 46, 842–848.
- Brain Trauma Foundation (2007). Guidelines for the management of severe traumatic brain injury. Infection prophylaxis. *Journal of Neurotrauma*, 24, S26–S31.
- Bratton, S. L., Chestnut, R. M., Ghajar, J., Connell Hammond, F. F., Harris, O. A., Hartl, R., et al. (2007). Guidelines for the management of severe traumatic brain injury. VI. Indications for intracranial pressure monitoring. *Journal of Neurotrauma*, 24(Suppl. 1), S37–S44.
- Brawanski, A. (2006). Relationship of rebleeding and external ventricular drainage in patients with subarachnoid hemorrhage of aneurismal origin. *Neurosurgery Review*, 29, 19–20.
- British Society for Antimicrobial Chemotherapy. (2000). The management of neurosurgical patients with postoperative bacterial or aseptic meningitis or external ventricular drain-associated ventriculitis. *British Journal of Neurosurgery*, 14, 7–12.
- Broadbelt, A., & Stoodley, M. (2007). CSF pathways: A review. *British Journal of Neurosurgery*, 21, 510–520.
- Byers, S. E., O'Malley, G., Alli, F., & Dominici, P. G. (2006). Lumbar puncture: A comparison of lateral recumbent and sitting position in the number of attempts and ease of procedure. *Annals of Emergency Medicine*, 48(4 Supp. 1), 40.
- Calfee, D. P., & Farr, B. M. (2002). Comparison of four antiseptic preparations for skin in the prevention of contamination of percutaneously drawn blood cultures: A randomized trial. *Journal of Clinical Microbiology*, 40(5), 1660–1665.
- Cartwright, C., & Wallace, D. (2007). *Nursing care of the pediatric neurosurgery patient*. New York, NY: Springer-Verlag Berlin Heidelberg.
- Chang, W. N., Lu, C.H., Huang, C.R., Tsai, N. W., Chuang, Y. C., Chang, Y. C., et al. (2008). Changing epidemiology of adult bacterial meningitis in southern Taiwan: A hospital-based study. *Infection*, 36, 15–22.
- Clevenger, V. (1990). Nursing management of lumbar drains. *Journal of Neuroscience Nursing*, 22(4), 227–231.
- Connolly, E. S., McKhann, G. M., Huang, J., & Choudhri, T. E. (2002). *Fundamentals of operative techniques in neurosurgery*. New York, NY: Thieme Medical Publishers, Inc.
- Coplin, W. M., Avellino, A. M., Kim, D. K., Winn, H. R., & Grady, M. S. (1999). Bacterial meningitis associated with lumbar drains: A retrospective cohort study. *Journal of Neurology, Neurosurgery, and Psychiatry*, 67, 468–473.
- Coselli, J. S., LeMaire, S. A., Schmittling, Z. C., & Koksoy, C. (2000). Cerebrospinal fluid drainage in thoracoabdominal aortic surgery. *Seminars in Vascular Surgery*, 13(4), 308–314.

- Craighead, M. C. K, Matt, M. P., Davis, S. B., McMullen, K. M., Lessly, D., & Warren, D. K. (2008). *American Journal of Infection Control*, 36, E199–E200.
- Crawford, E. S., Svensson, L. G., Hess, K. R., Shenaq, S. S., Coselli, J. S., Safi, H. J., et al. (1991). A prospective randomized study of cerebrospinal fluid drainage to prevent paraplegia after high-risk surgery on the thoracoabdominal aorta. *Journal of Vascular Surgery*, 13(1), 36–45.
- Criddle, L. (2007). Ask the experts. *Critical Care Nurse*, 27, 78–81.
- Crosby, C. (2008, Spring). Chlorhexidine question may be for FDA. [Letter to the Editor]. *Anesthesia Patient Safety Foundation*, 23(3).
- Czosnyka, M., & Pickard, J. D. (2004). Monitoring and interpretation of intracranial pressure. *Journal of Neurology, Neurosurgery, and Psychiatry*, 75, 813–821.
- Dailey, P. A. (2009, Summer). Chlorhexidine or povidone-iodine: Do we follow the guidelines or package insert? [Letter to the Editor]. *California Society of Anesthesiologists*, 45–47.
- Darouiche, R. O., Wall, M. J., Kamal, M. F. I., Otterson, M. F., Webb, A. L., Carrick, M. M., et al. (2010). Chlorhexidine-alcohol versus povidone-iodine for surgical-site antisepsis. *The New England Journal of Medicine*, 362, 18–26.
- Dasic, D., Hanna, S. J., Bonjanic, S., & Kerr, R. S. C. (2006). External ventricular drain infection: The effect of a strict protocol on infection rates and a review of the literature. *British Journal of Neurosurgery*, 20, 296–300.
- Davis, J. W., Davis, I. C., Bennick, L. D., Hysell, S. E., Curtis, B. V., Kaups, K. L., et al. (2004). Placement of intracranial pressure monitors: Are “normal” coagulation parameters necessary? *The Journal of Trauma*, 57, 1173–1177.
- Dellinger, E. P., Gross, P. A., Barrett, T. L., Krause, P. J., Martone, W. J., Mc Gowan, J. E., et al. (1994). Quality standard for antimicrobial prophylaxis in surgical procedures. *Clinical Infectious Diseases*, 18, 422–427.
- Drake, J. M., & Crawford, M. (2005). Near-miss injection of an anesthetic agent into a cerebrospinal fluid external ventricular drain: Special report. *Neurosurgery*, 56, E1161.
- Edgton-Winn, M., & Perry, M. (2006, October). EVD Removal. In *Corporate manual, patient care* (pp. 1–2). Kingswood, Australia: Liverpool Health Service.
- Ehtisham, A., Taylor, S., Bayless, L., Klein, M., & Janzen, J. (2009). Placement of external ventricular drains and intracranial pressure monitors by neurointensivists. *Neurocritical Care*, 10, 241–247.
- Ellenby, M. S., Tegtmeyer, K., Lai, S., & Braner, D. A. V. (2006). Lumbar Puncture. *New England Journal of Medicine*, 355, e12.
- Evans, R. W., Armon, C., & Frohman, Goodin, D. S. (2000). Assessment: prevention of post-lumbar puncture headaches: Report of the Therapeutics and Technology Assessment Subcommittee of the American Academy of Neurology. *Neurology*, 55(7), 909–914.
- Fan, J. Y. (2004). Effect of backrest position on intracranial pressure and cerebral perfusion pressure in individuals with brain injury: A systematic review. *Journal of Neuroscience Nursing*, 36(5), 278–88.
- Fan, J. Y., Kirkness, C., Vicini, P., Burr, R., & Mitchell, P. (2008). Intracranial pressure waveform morphology and intracranial adaptive capacity. *American Journal of Critical Care*, 17, 545–554.
- Fernandez, A., Schmidt, J. M., Claassen, J., Paavlicova, M., Huddlestone, D., Kreiter, K. T., et al. (2007). Fever after subarachnoid hemorrhage risk factors and impact on outcome. *Neurology*, 68, 1013–1019.
- Fernandez, S. R., Taboada, M., Ulloa, B., Rodriguez, J., Massid, A., & Alvarez, J. (2010). Needle-induced paresthesiae during single-shot spinal anesthesia: A comparison of sitting versus lateral decubitus position. *Regional Anesthesia and Pain Medicine*, 35(1), 41–44.
- Ferre, R. M., Sweeney, T. W., & Strout, T. D. (2009). Ultrasound identification of landmarks preceding lumbar puncture: A pilot study. *Journal of Emergency Medicine*, 26, 276–277.
- Fichtner, J., Güresir, E., Seifert, V., & Raabe, A. (2010). Efficacy of silver-bearing external ventricular drainage catheters: A retrospective analysis. *Journal of Neurosurgery*, 112(4), 840–846.
- Fields, J. D., Lansberg, M. G., Skirboll, S. L., Kurien, P. A., & Wijman, C. A. C. (2006). “Paradoxical” transtentorial herniation due to CSF drainage in the presence of a hemispherectomy. *Neurology*, 67, 1513–1514.
- Fountas, K. N., Kapsalaki, E. Z., Machinis, T., Karampelas, I., Smisson, H. F., & Robinson, J. S. (2006). Review of the literature regarding the relationship of rebleeding and external ventricular drainage in patients with subarachnoid hemorrhage of aneurismal origin. *Neurosurgery Review*, 29, 14–18.
- Forsythe, A., Gupta, A., & Cohen, S. P. (2009). Retained intrathecal catheter fragment after spinal drain insertion. *Regional Anesthesia and Pain Medicine*, 34(4), 375–378.
- Frank, J. L. (1995). Large hemispheric infarction, deterioration, and intracranial pressure. *Neurology*, 45, 1286–1290.
- Frieman, T. M., & Spiegelberg, A. (2008). Mounting device for external cerebrospinal fluid drainage: The Freiburg Stativ. *Acta Neurochirurgica*, 150, 1081–1085.
- Frontera, J. A., Fernandez, A., Schmidt, M. J., Claassen, J., Wartenberg, K. E., Badjatia, N., et al. (2008). Impact of nosocomial infectious complications after subarachnoid hemorrhage. *Neurosurgery*, 62, 80–87.
- Ganjoo, P., Sejwal, S., Sinha, S., Tandon, M. S., & Daljit, D. S. (2009). Intermittent lumbar drainage as a viable treatment option for cerebrospinal fluid rhinorrhea complicating pituitary surgery. *The Internet Journal of Anesthesiology*, 20(2). Retrieved April 25, 2011, from [www.ispub.com/journal/the\\_internet\\_journal\\_of\\_anesthesiology/volume\\_20\\_number\\_2/article/intermittent-lumbar-drainage-as-a-viable-treatment-option-for-cerebrospinal-fluid-rhinorrhea-complicating-pituitary-surgery.html](http://www.ispub.com/journal/the_internet_journal_of_anesthesiology/volume_20_number_2/article/intermittent-lumbar-drainage-as-a-viable-treatment-option-for-cerebrospinal-fluid-rhinorrhea-complicating-pituitary-surgery.html).
- Gardner, P. A., Engh, J. E., Atteberry, D., & Moossy, J. J. (2009). Hemorrhage rates after external ventricular drain placement. *Journal of Neurosurgery*, 110, 1021–1025.
- Governale, L. S., Fein, N., Logsdon, J., & Black, P. M. (2008). Techniques and complications of external lumbar drainage for normal pressure hydrocephalus. *Neurosurgery*, 63(4 Supp 2), 379–384.
- Grady, R. E., Horlocker, T. T., Brown, R. D., Maxson, P. M., Schroeder, D. R., & Mayo Perioperative Outcomes Group. (1999). Neurologic complications after placement of cerebrospinal fluid drainage catheters and needles in anesthetized patients: Implications for regional anesthesia. *Anesthesia and Analgesics*, 88, 388–392.
- Gray, L. D. & Fedorko, D. P. (1992). Laboratory diagnosis of bacterial meningitis. *Clinical Microbiology Reviews*, 5, 130–145.

- Greenberg, M. (2006). *Handbook of Neurosurgery* (6th ed.). New York: Thieme.
- Guardado, A. R., Blanco, A., Asensi, V., Perez, F., Rial, J. C., Pintado, J. C., et al. (2008). Multidrug-resistant *Acinetobacter* meningitis in neurosurgical patients with intraventricular catheters: Assessment of different treatments. *Journal of Antimicrobial Chemotherapy*, *61*, 908–913.
- Guzel, A., Ozekinci, T., Ozkan, U., Celik, Y., Ceviz, A., & Belen, D. (2009). Evaluation of the skin flora after chlorhexidine and povidine-iodine preparation in neurosurgical practice. *Surgical Neurology*, *71*, 201–210.
- Hader, W. J. & Steinbok, P. (2000). The value of routine cultures of the cerebrospinal fluid in patients with external ventricular drains. *Neurosurgery*, *46*, 1149–1155.
- Hasbun, R., Abrahams, J., Jekel, J., & Quagliarello, V. J. (2001). Computed tomography of the head before lumbar puncture in adults with suspected meningitis. *New England Journal of Medicine*, *345*(24), 1727–1733.
- Hibbard, J. (2005). Analyses comparing the antimicrobial activity and safety of current antiseptic agents: a review. *Journal of Infusion Nursing*, *28*, 194–207.
- Hickey, J. (2009). *The clinical practice of neurological and neurosurgical nursing* (6th ed.). Philadelphia: Lippincott Williams & Wilkins.
- Hoefnagel, D., Dammers, R., Ter Laak-Poort, M. P., & Avezaat, C. J. (2008). Risk factors for infections related to external ventricular drainage. *Acta Neurochirurgica*, *150*, 209–214.
- Hoekema, D., Schmidt, R. H., & Ross, I. (2007). Lumbar drainage for subarachnoid hemorrhage: Technical considerations and safety analysis. *Neurocritical Care*, *7*, 3–9.
- Horlocker, T. T., Abel, M. D., Messick, J. M., & Schroeder, D. R. (2003). Small risk of serious neurologic complications related to lumbar epidural catheter placement in anesthetized patients. *Anesthesia and Analgesics*, *96*, 1547–1552.
- Houle, P. J., Vender, J. R., Fountas, K., McDonnell, D. E., Fick, J. R., & Robinson, J. S. (2000). Pump-regulated lumbar subarachnoid drainage. *Neurosurgery*, *4*, 929–932.
- Howell, S., & Driver, R. (2008). Unintentional intracerebroventricular administration of etomidate and rocuronium. *Anesthesia and Analgesia*, *106*, 520–522.
- Huyette, D. R., Turnbow, B. J., Kaufman, C., Vaslow, D. F., Whiting, B. B., & Oh, M. Y. (2008). Accuracy of the freehand pass technique for ventriculostomy catheter placement: Retrospective assessment using computed tomography scans. *Journal of Neurosurgery*, *108*, 88–91.
- James, H. F., & Bradley, J. S. (2008). Management of complicated shunt infections: a clinical report. *Journal of Neurosurgery Pediatrics*, *1*, 223–228.
- Joffe, A. R. (2007). Lumbar puncture and brain herniation in acute bacterial meningitis: A review. *Journal of Intensive Care Medicine*, *22*(4), 194–207.
- Johnson, K. S., & Sexton, D. J. (2009, September 30). Cerebrospinal fluid: Physiology and utility of an examination in disease states. Retrieved February 8, 2010, from www.uptodate.com.
- Kakarla, U. K., Kim, L. J., Chang, S. W., Theodore, N., & Spetzler, R. F. (2008). Safety and accuracy of bedside external ventricular drain placement. *Operative Neurosurgery*, *63*, 162–167.
- Kase, C. S., & Wolf, P. A. (1993). Cerebellar infarction: Upward transtentorial herniation after ventriculostomy. *Stroke*, *24*, 1096–1098.
- Kerr, M. E., Weber, B. B., Sereika, S. M., Wilberger, J., & Marion, D. W. (2001). Dose response to cerebrospinal fluid drainage on cerebral perfusion in traumatic brain-injured adults. *Neurosurgical Focus*, *11*, 1–7.
- Kirkness, C. J., Mitchell, P. H., Burr, R. L., March, K. S., & Newell, D. W. (2000). Intracranial pressure waveform analysis: Clinical and research implications. *Journal of Neuroscience Nursing*, *32*, 271–277.
- Kleine, T. O., Zwerenz, P., Zofel, P., & Shiratori, K. (2003). New and old diagnostic markers of meningitis in cerebrospinal fluid (CSF). *Brain Research Bulletin*, *61*, 287–297.
- Klimo, P., Jr., Kestle, J. R., MacDonald, J. D., & Schmidt, R. H. (2004). Marked reduction of cerebral vasospasm with lumbar drainage of cerebrospinal fluid after subarachnoid hemorrhage. *Journal of Neurosurgery*, *2*, 215–224.
- Klopfenstein, J. D., Kim, L. J., Feiz-Erfan, I., Hott, J. S., Goslar, P., & Zabramski, J. M. (2004). Comparison of rapid and gradual weaning from external ventricular drainage in patients with aneurysmal subarachnoid hemorrhage: A prospective randomized trial. *Journal of Neurosurgery*, *100*, 225–229.
- Ko, K. & Conforti, A. (2003). Training protocol for intracranial pressure monitor placement by non-neurosurgeons: 5-year experience. *The Journal of Trauma Injury, Infection, and Critical Care*, *55*(3), 480–484.
- Komotar, R. J., Zacharia, B. E., Mocco, J., Kaiser, M. G., Frucht, S. J., & McKhann, G. M. (2008). Cervical spine disease may result in a negative lumbar spinal drainage trial in normal pressure hydrocephalus: Case report. *Neurosurgery*, *63* (4 Suppl. 2), 315.
- Korinek, A. M., Reina, M., Boch, A. L., Rivera, A. O., De Bels, D., & Puybasset, L. (2005). Prevention of external ventricular drain—related ventriculitis. *Acta Neurochirurgica*, *147*, 39–46.
- Koskinen, L., & Olivecrona, M. (2005). Clinical experience with the intraparenchymal intracranial pressure monitoring Codman Microsensor System. *Neurosurgery*, *56*, 693–8.
- Legal Eagle Eye Newsletter. (2007, April). Ventriculostomy catheter: Nurse-infused mixture meant for IV. *15*, 6. Retrieved April 25, 2011, from www.nursinglaw.com/apr07ide5.pdf.
- Leib, S. L., Boscacci, R., Gratzl, O., & Zimmerli, W. (1999). Predictive value of cerebrospinal fluid (CSF) lactate level versus CSF/ blood glucose ratio for the diagnosis of bacterial meningitis following neurosurgery. *Clinical Infectious Disease*, *29*, 69–74.
- Lemaire, J. J., Khalil, T., Cervenansky, F., Gindre, G., Boire, J. Y., Bazin, J. E., et al. (2002). Slow pressure waves in the cranial enclosure. *Acta Neurochirurgica*, *144*, 243–254.

- Lenfeldt, N., Koskinen, L. O., Bergenheim, A. T., Malm, J., & Eklund, A. (2007). CSF pressure assessed by lumbar puncture agrees with intracranial pressure. *Neurology*, *68*, 155–158.
- Leverstein-van Hall, M. A., Hopmans, T. E., Berkelback van der Sprenkel, J. W., Blok, H., van der Mark, W., et al. (2010). A bundle approach to reduce the incidence of external ventricular and lumbar drain-related infections. *Journal of Neurosurgery*, *112*, 345–353.
- Littlejohns, L. (2009). Monitoring technologies in critically ill neuroscience Patients. In American Association of Critical-Care Nurses & American Association of Neuroscience Nurses, *AACN-AANN Protocols for Practice* (pp. 83–92). Sudbury, MA: Jones & Bartlett Publishers.
- Littlejohns, L. R., & Trimble, B. (2005). Ask the experts: Priming EVD systems. *Critical Care Nurse*, *25*(3), 57–59.
- Lozier, A. P., Sciacca, R. R., Romagnoli, M. F., & Connolly, S. E. (2002). Ventriculostomy-related infections: A critical review of the literature. *Neurosurgery*, *51*, 170–182.
- MacSween, K. F., Bicanic, T., Brouwer, A. E., Marsh, H., Macallan, D. C., & Harrison, T. S. (2005). Lumbar drainage for control of raised cerebrospinal fluid pressure in cryptococcal meningitis: Case report and review. *Journal of Infection*, *51*, e221–e224.
- March, K., & Madden, L. (2009). Intracranial pressure monitoring. In American Association of Critical-Care Nurses & American Association of Neuroscience Nurses, *AACN-AANN Protocols for Practice: Monitoring Technologies in Critically Ill Neuroscience Patients* (pp. 35–69). Sudbury, MA: Jones & Bartlett Publishers.
- Marmarou, A., Bergsneider, M., Klinge, P., Relkin, N., & Black, P. M. (2005). The value of supplemental prognostic tests for the preoperative assessment of idiopathic normal-pressure hydrocephalus. *Neurosurgery*, *3*(Suppl.), S17–S28, discussion ii–v.
- Mayhall, G. C., Archer, N. H., Lamb, V. A., Spadora, A. C., Baggett, J. W., Ward, J. D., et al. (1984). Ventriculostomy-related infections. *New England Journal of Medicine*, *310*, 553–559.
- McCance, K. L., Huether, S. E., Brashers, V. L., & Rote, N. S. (2010). *Pathophysiology: The biologic basis for disease in adults and children* (6th ed.). Philadelphia: Mosby Elsevier.
- Medtronic, Inc. (2008). Duet™ external drainage and monitoring system [Video]. Retrieved April 27, 2011, from [www.medtronic.com/neurosurgery/main\\_duet.html](http://www.medtronic.com/neurosurgery/main_duet.html).
- Meyer, J. (2009). A broad-spectrum look at catheter-related bloodstream infections. *Journal of Infusion Nursing*, *32*, 80–86.
- Miglis, M. G., & Levine, D. N. (2010). Intracranial venous thrombosis after placement of lumbar drain. *Neurocritical Care*, *12*, 83–87.
- Miyazawa, K., Shiga, Y., Hasegawa, T., Endoh, M., Okita, N., Higano, S., et al. (2003). CSF hypovolemia vs intracranial hypotension in “spontaneous intracranial hypotension syndrome.” *Neurology*, *60*, 941–947.
- Moore, K. L., & Dalley, A. F. (1999). *Clinically oriented anatomy* (4th ed.). Baltimore: Lippincott Williams & Wilkins.
- Munch, E. C., Bauhuf, C., Horn, P., Roth, H. R., Schmiedek, P., & Vajkoczy, P. (2001). Therapy of malignant intracranial hypertension by controlled lumbar cerebrospinal fluid drainage. *Critical Care Medicine*, *5*, 976–981.
- Muraskin, S. I., Roy, R. C., & Patrozza, P. H. (2007). Overdrainage of cerebrospinal fluid during central venous catheter exchange in a patient with an external ventricular drain. *Anesthesia and Analgesia*, *105*, 1519–1520.
- Muttaiyah, S., Ritchie, S., John, S., Mee, E., & Roberts, S. (2010). Efficacy of antibiotic-impregnated external ventricular drain catheters. *Journal of Clinical Neuroscience*, *17*, 296–298.
- Muttaiyah, S., Ritchie, S., Upton, A., & Roberts, S. (2008). Clinical parameters do not predict infection in patients with external ventricular drains: A retrospective observational study of daily cerebrospinal fluid analysis. *Journal of Medical Microbiology*, *57*, 207–209.
- Ngo, Q. N., Ranger, A., Singh, R. N., Kornecki, A., Seabrook, J. A., & Fraser, D. D. (2009). External ventricular drains in pediatric patients. *Pediatric Critical Care Medicine*, *10*, 346–351.
- O’Connor, G., Gingrich, R., & Moffat, M. (2007). The effect of spinal needle design, size, and penetration angle on dural puncture cerebral spinal fluid loss. *The American Association of Nurse Anesthetists Journal*, *75*(2), 111–116.
- O’Neill, B. R., Velez, D. A., Braxton, E. E., Whiting, D., & Oh, M. Y. (2008). A survey of ventriculostomy and intracranial pressure monitor placement practices. *Surgical Neurology*, *70*, 268–273.
- O’Grady, N. P., Alexander, M., Burns, L. A., Dellinger, E. P., Garland, J., Heard, S. O., et al. (2011). Guidelines for the prevention of intravascular catheter-related infections. Retrieved April 25, 2011, from [www.cdc.gov/hicpac/BSI/BSI-guidelines-2011.pdf](http://www.cdc.gov/hicpac/BSI/BSI-guidelines-2011.pdf).
- Overstreet, M. (2003). Clinical queries: Managing a lumbar drain. *Nursing* *2003*, *33*(3), 74–75.
- Paldino, M., Mogilner, A. Y., & Tenner, M. S. (2003). Intracranial hypotension syndrome: A comprehensive review. *Neurosurgery Focus*, *15*, ECP2.
- Pfaußler, B., Beer, R., Engelhardt, K., Kemmler, G., Mohsenipour, I., & Schmutzhard, E. (2004). Cell index—a new parameter for the early diagnosis of ventriculostomy (external ventricular drainage)-related ventriculitis in patients with intraventricular hemorrhage? *Acta Neurochirurgica*, *146*, 477–481.
- Pope, W. (1998). External ventriculostomy: A practical application for the acute care nurse. *Journal of Neuroscience Nursing*, *30*, 185–190.
- Pudenz, R. H. (1989). *External lumbar drainage*. Goleta, CA: Pudenz-Schulte.
- Razmkon, A., & Bakhtazad, A. (2009). Maintaining CSF drainage at external ventricular drains may help prevent catheter-related infection. *Acta Neurochirurgica*, *515*, 985.
- Ravi, R., & Morgan, R. J. (2003). Intracranial pressure monitoring. *Current Anaesthesia & Critical Care*, *14*, 229–235.
- Rose, J. C., & Mayer, S. A. (2004). Optimizing blood pressure in neurologic emergencies. *Neurocritical Care*, *1*, 287–299.
- Sade, B., Mohr, G., & Frenkiel, S. (2006). Management of intraoperative cerebrospinal fluid leak in transnasal transsphenoidal pituitary microsurgery: Use of post-operative lumbar drain and sellar reconstruction without fat packing. *Acta Neurochirurgica*, *1*, 13–19.

- Safi, H. J., Bartoli, S., Hess, K. R., Shenaq, A. A., Viets, J. R., Butt, G. R., et al. (1994). Neurologic deficit in patient at high risk with thoracoabdominal aortic aneurysms: The role of cerebral spinal fluid drainage and distal aortic perfusion. *Journal of Vascular Surgery*, 20, 434–444.
- Safi, H. J., Hess, K. R., Randel, M., Hiopoulos, D. C., Baldwin, J. C., Mootha, R. K., et al. (1996). Cerebrospinal fluid drainage and distal aortic perfusion: Reducing neurologic complications in repair of thoracoabdominal aortic aneurysm types I and II. *Journal of Vascular Surgery*, 23, 223–229.
- Samadani, U., Huang, J. H., Baranov, D., Zager, E. L., & Grady, M. S. (2003). Intracranial hypotension after intraoperative lumbar cerebrospinal fluid drainage. *Neurosurgery*, 1, 148–151.
- Sandoval, M., Shestak, W., Sturmman, K., & Hsu, C. (2004). Optimal patient position, measured by ultrasonography. *Emergency Radiology*, 10, 179–181.
- Schade, R. P., Schinkel, J., Visser, L. G., Van Dijk, J. M. C., Voormolen, J. H. C., & Kuijjer, E. J. (2005). Bacterial meningitis caused by the use of ventricular or lumbar cerebrospinal fluid catheters. *Journal of Neuroscience*, 102, 229–234.
- Schade, R. P., Schinkel, J., Roelandse, F. W. C., Geskus, R. B., Visser, L. G., van Dijk, M. C., et al. (2006). Lack of value of routine analysis of cerebrospinal fluid for prediction and diagnosis of external drainage-related bacterial meningitis. *Journal of Neurosurgery*, 104, 101–108.
- Scheithauer, S., Burgel, U., Ryand, Y. M., Hasse, G., Schiefer, J., Koch, S., et al. (2009). Prospective surveillance of drain associated meningitis/ventriculitis in a neurosurgery and neurology intensive care unit. *Journal of Neurology Neurosurgery and Psychiatry*, 80, 1381–1385.
- Schwab, S., Aschoff, A., Spanger, M., Albert, F., & Hacke, W. (1996). The value of intracranial pressure monitoring in acute hemispheric stroke. *Neurology*, 47, 393–398.
- Seinfeld, J., Sawyer, M., & Rabb, C. H. (2007). Successful treatment of paradoxical cerebral herniation by lumbar epidural blood patch placement: Technical case report. *Neurosurgery*, 61 (Suppl. 1), E175.
- Sexton, D. J. (2009, September 30). Neurologic complications of bacterial meningitis in adults. Retrieved February 7, 2010 from [www.uptodate.com/contents/neurologic-complications-of-bacterial-meningitis-in-adults](http://www.uptodate.com/contents/neurologic-complications-of-bacterial-meningitis-in-adults).
- Singha, S. K., Chatterjee, N., & Neema, P. K. (2009). Reverse herniation of brain: A less recognized complication in a patient with midline posterior fossa tumor postendoscopic third ventriculostomy. *Journal of Neurosurgical Anesthesiology*, 21, 354–355.
- Stefani, R., & Rasulo, F. (2008). Intracranial pressure monitoring. *European Journal of Anaesthesiology*, 25 (Suppl. 42), 192–195.
- Straus, S. E., Thorpe, K. E., & Holroyd-Leduc, J. (2006). How do I perform a lumbar puncture and analyze the results to diagnose bacterial meningitis? *Journal of the American Medical Association*, 296, 2012–2022.
- Sudlow, C. L. M., & Warlow, C. P. (2009). Posture and fluids for preventing post-dural puncture headache: Review. *The Cochrane Library*, Issue 1, 1–20.
- Tanner, J., Woodings, D., & Moncaster, K. (2006). *Preoperative hair removal to reduce surgical site infection*. [Abstract]. Retrieved from Cochrane Database of Systematic Reviews 2006.
- Thoennissen, J., Herkner, H., Lang, W., Domanovits, H., Laggner, A. N., & Mullner, M. (2001). Does bed rest after cervical or lumbar puncture prevent headache? A systematic review and meta-analysis. *Journal of Canadian Medical Association*, 165(10), 1311–1316.
- Thomas, S. R., Jamieson, D. R. S., & Muir, K. W. (2000). Randomised controlled trial of atraumatic versus standard needles for diagnostic lumbar puncture. *British Journal of Medicine*, 321, 986–990.
- Thompson, H. J. (2000). Managing patients with lumbar drainage devices. *Critical Care Nurse*, 20(5), 59–68.
- Thundiyl, J. G., O'Brien, J. F., & Papa, L. (2007). Optimal positioning for lumbar puncture: Lateral decubitus or sitting? *Annals of Emergency Medicine*, 50(3 Suppl. 1), S11.
- Toma, A. K., Camp, S., Watkins, L. D., Grieve, J., & Kitchen, N. D. (2009). External ventricular drain insertion accuracy: Is there a need for change in practice? *Neurosurgery*, 65, 1197–1201.
- Tunkel, A. R. (2009, September 30). Clinical features and diagnosis of acute bacterial meningitis in adults. Retrieved February 7, 2010, from [www.uptodate.com/contents/clinical-features-and-diagnosis-of-acute-bacterial-meningitis-in-adults](http://www.uptodate.com/contents/clinical-features-and-diagnosis-of-acute-bacterial-meningitis-in-adults).
- Tunkel, A. R., & Scheld, W. M. (1993). Pathogenesis and pathophysiology of bacterial meningitis. *Clinical Microbiology Reviews*, 6, 118–136.
- Vallejo, M. C., Mandell, G. L., Sabo, D. P., & Ramanathan, S. (2009). Postdural puncture headache: A randomized comparison of five spinal needles in obstetric patients. *Anesthesia and Analgesia*, 91, 916–920.
- van Aken, M. O., Feelders, R. A., de Marie, S., van de Berge, J. H., Dallenga, A. H., Delwel, E. J., et al. (2004). Cerebrospinal fluid leakage during transsphenoidal surgery: Postoperative external lumbar drainage reduces the risk for meningitis. *Pituitary*, 7(2), 89–93.
- van de Beek, D., de Gans, J., Spanjaard, L., Weisfelt, M., Reitsma, J. B., & Vermeulen, M. (2004). Clinical features and prognostic factors in adults with bacterial meningitis. *New England Journal of Medicine*, 351, 1849–1859.
- van de Beek, D., Drake, J. M., & Tunkel, A. R. (2010). Nosocomial bacterial meningitis. *New England Journal of Medicine*, 363, 146–154.
- Varelas, P. (2006). Clipping or coiling of ruptured cerebral aneurysm and shunt dependent hydrocephalus. *Neurocritical Care*, 4, 224.
- Vender, J. R., Houle, P., Flannery, A. M., Fryburg, K., & Lee, M. R. (2000). Pump-regulated cerebrospinal fluid drainage. *Pediatric Neurosurgery*, 32(2), 69–72.
- Vourc'h, G. (1963). Continuous cerebrospinal fluid drainage by indwelling spinal catheter. *British Journal of Anaesthesia*, 35, 118–120.
- Walker, J. (2007). Patient preparation for safe removal of surgical drains. *Nursing Standard*, 21(49), 39–41.
- Weaver, K. D., Wiseman, D. B., Farber, M., Ewend, M. G., Marston, W., & Keagy, B. A. (2001). Complications of lumbar drainage after thoracoabdominal aortic aneurysm repair. *Journal of Vascular Surgery*, 4, 623–627.

- Weisfelt, M., van de Beek, D., Spanjaard, L., & de Gans, J. (2007). Nosocomial bacterial meningitis in adults: A prospective series of 50 cases. *Journal of Hospital Infection*, *66*, 71–78.
- Whedon, J. M., & Glassey, D. (2009). Cerebrospinal fluid stasis and its clinical significance. *Alternative Therapies in Health & Medicine*, *15*(3), 54–60.
- Wiegand, D., & Carlson, K. (Eds.). (2005). *AACN Procedure Manual for Critical Care*. (5th ed.) St. Louis, MO: Elsevier Saunders.
- Williams, J., Lye, D. C. B., & Umaphathi, T. (2008). Diagnostic lumbar puncture: Minimizing complications. *Journal of Internal Medicine*, *38*, 587–591.
- Willschke, H., Bosenberg, A., Marhofer, P., Willschke J., Schwindt, J., Weintraud, M., et al. (2007). Epidural catheter placement in neonates: Sonoanatomy and feasibility of ultrasonographic guidance in term and preterm neonates. *Regional Anesthesia and Pain Medicine*, *32*(1), 34–40.
- Woodward, S., Addison, C., Shah, S., Brennan, F., MacLeod, A., & Clements, M. (2002). Benchmarking best practice for external ventricular drainage. *British Journal of Nursing*, *11*, 47–53.
- Wong, G. K. & Poon, W. S. (2008). Use of ventricular cerebrospinal fluid lactate measurement to diagnose cerebrospinal fluid infection in patients with intraventricular hemorrhage. *Journal of Clinical Neuroscience*, *15*, 654–655.
- Zabramski, J. M., Whiting, D., Darouiche, R. O., Horner, T. G., Olson, J., Robertson, C., et al. (2003) Efficacy of antimicrobial-impregnated external ventricular drain catheters: A prospective, randomized, controlled trial. *Journal Neurosurgery*, *98*, 725–730.
- Zarrouk, V., Vassor, I., Bert, F. Bouccara, D., Kalamarides, M., Bendersky, N., et al. (2007). Evaluation of the management of postoperative aseptic meningitis. *Clinical Infectious Diseases*, *44*, 1555–1559.
- Ziai, W. C., & Lewin, III, J. J. (2009). Improving the role of intraventricular antimicrobial agents in the management of meningitis. *Current Opinion in Neurology*, *22*, 277–282.

## Bibliography

- Ahrens, T., Peck, J. C., & Tucker, M. K. (1995). Frequency requirements for zeroing transducers in hemodynamic monitoring. *American Journal of Critical Care*, *4*, 466–471.
- Al-Tamimi, Y. Z., Helmy, A., Bavetta, S., & Price, S. J. (2009). Assessment of zero drift of the Codman intracranial pressure monitor: A study of two neurointensive care units. *Neurosurgery*, *64*(1), 94–98.
- Archer, B. D. (1993). Computed tomography before lumbar puncture in acute meningitis: A review of the risks and benefits. *Journal of Canadian Medical Association*, *148*(6), 961–965.
- Association of Perioperative Registered Nurses (AORN). (2009). *Perioperative standards and recommended practices*. Denver, CO: AORN.
- Avery, R. A., Mistry, R. D., Shah, S. S. Boswinkel, J, Huh, J. W., Ruppe, M. D., et al. (2010). Patient position during lumbar puncture has no meaningful effect on cerebrospinal fluid opening pressure in children. *Journal of Child Neurology*, 1–4.
- Barker II, F. G. (2007). Efficacy of prophylactic antibiotics against meningitis after craniotomy: A meta-analysis. *Neurosurgery*, *60*, 887–894.
- Boon, J. M., Abrahams, P. H., Meiring, J. H., & Welch, T. (2004). Lumbar puncture: Anatomical review of a clinical skill. *Clinical Anatomy*, *17*, 544–553.
- Braune, H. J., & Huffmann, G. A. (1992). A prospective double-blind clinical trial, comparing the sharp quinke needle (22G) with an “atraumatic” needle (22G) in the induction of post-lumbar puncture headache. *ACTA Neurologica Scandinavica*, *86*, 50–54.
- Dieterich, M., & Brandt, T. (1985). Is obligatory bedrest after lumbar puncture obsolete? *European Archives of Psychiatry and Neurological Sciences*, *235*, 71–75.
- Farley, A., & McLafferty, E. (2008). Lumbar Puncture. *Nursing Standard*, *22*, 46–48.
- Gardner, R. M. (1996). Accuracy and reliability of disposable pressure transducers coupled with modern pressure monitors. *Critical Care Medicine*, *24*, 879–882.
- Harris, C., Smith, R., Helmer, S., Gorecki, J., & Rody, B. (2002). Placement of intracranial pressure monitors by non-neurosurgeons. *The American Surgeon*, *68* (9), 787–90.
- Heble, J. R., & Neal, J. M. (2006). Editorial: Infectious complications: A new practice advisory. *Regional Anesthesia and Pain Medicine*, *31*(4), 289–290.
- Heble, J.R. (2006). The importance and implications of aseptic techniques during regional anesthesia. *Regional Anesthesia and Pain Medicine*, *31*(4), 311–323.
- Hess, J. H. (1991). Post-dural puncture headache: A literature review. *Journal of the American Association of Nurse Anesthetists*, *59*(6), 549–555.
- Howard, S. C, Gajjar, A., Ribeiro, R. C., Rivera, G. K., Rubnitz, J. E., Sundlund, J. T., et al. (2000). Safety of lumbar puncture for children with acute lymphoblastic leukemia and thrombocytopenia. *JAMA*, *284*(17) 2222–2224.
- Koul, R., Chacko, A., Javed, H., Jain, R., Ganesh, A., & Srinivasan, S. (2002). Syndrome of cerebrospinal fluid hypovolemia following lumbar puncture cerebrospinal fluid lead in a patient with idiopathic intracranial hypertension. *Journal of Child Neurology*, *17*(1), 77–79.
- Kiyoyama, T., Tokuda, Y., Shiiki, S., Hachiman, T., Shimasaki, T., & Endo, K. (2009) Isopropyl alcohol compared with isopropyl alcohol plus povidone-iodine as skin preparation for prevention of blood culture contamination. *Journal of Clinical Microbiology*, *47*(1), 54–58.
- Lambert, D. H., Hurley, R. J., Hertwig, L., & Datta, S. (1997). Role of needle gauge and tip configuration in the production of lumbar puncture headache. *Regional Anesthesia*, *22*(1), 66–72.

- Leeper, B., & Lovasik, D. (2000). Cerebrospinal drainage systems: External ventricular and lumbar drains. In American Association of Critical-Care Nurses & American Association of Neuroscience Nurses, *AACN-AANN protocols for practice: Monitoring technologies in critically ill* (pp. 72–102). Sudbury, MA: Jones & Bartlett Publishers.
- Lewis, M. C., Lafferty, J. P., Sacks, M. S., Pallares, V. S., & TerRiet, M. (2000). How much work is required to puncture dura with tuohy needles? *British Journal of Anesthesia*, *85*(2), 238–241.
- Luostarinen, L., Heinonen, T., Luostarinen, M., & Salmivaara, A. (2005). Diagnostic lumbar puncture: Comparative study between 22-gauge pencil point and sharp bevel needle. *Journal of Headache and Pain*, *6*, 400–404.
- Marec-Berard, P., Bissery, A., Kebaili, K., Schell, M., Aubert, F., Gailard, S., et al. (2009). A positioning pillow to improve lumbar puncture success rate in paediatric haematology-oncology patients: a randomized controlled trial. *BMC Cancer*, *9*(21).
- Martinez-Manas, R. M., Santamarta, D., de Campos, J. M., & Ferre, E. (2000). Camino intracranial pressure monitor: Prospective study of accuracy and complications. *Journal of Neurology, Neurosurgery and Psychiatry*, *68*, 82–86.
- Martini, R. P., Deem, S., Yanez, N. D., Chesnut, R. M., Weiss, N. S., Daniel, S., et al. (2009). Management guided by brain tissue oxygen monitoring and outcome following severe traumatic brain injury. *Journal of Neurosurgery*, *111*, 644–649.
- Mimoz, O., Karim, A., Mercat, A., Cosseron, M., Falissard, B., Parker, F., et al. (1999). Chlorhexidine compared with povidone-iodine as skin preparation before blood culture: A randomized, controlled trial. *Annals of Internal Medicine*, *131*(11), 834–837.
- Ng, I., Lim, J., & Wong, H. (2004). Effects of head posture on cerebral hemodynamics: Its influences on intracranial pressure, cerebral perfusion pressure, and cerebral oxygenation. *Neurosurgery*, *54*, 593–598.
- Olivar, H., Bramhall, J. S., Rozet, I., Vavilala, M. S., Souter, M. J., & Lee, L. A., et al. (2007). Subarachnoid lumbar drains: A case series of fractured catheters and a near miss. *Canadian Journal of Anesthesia*, *54*(10), 829–834.
- Ramjam, J., & Rafflesath, J. (2004). *Intensive care service: Nursing policy and procedures - lumbar drain*. Retrieved February 25, 2010, from <http://intensivecarenet.hsnet.new.gov.au>.
- Report of Quality Standards Subcommittee of the American Academy of Neurology. (1993). Practice parameters: Lumbar puncture. *Neurology*, *43*, 625–627.
- Rimmer, L. (2006, January). *Managing the lumbar drain device: Keeping the nurse and physician on the same page*. Poster session presented at the meeting of the American Association of Critical Care Nurses, New Orleans, LA.
- The Royal Children's Hospital Melbourne. (2009). *External ventricular drains and ICP monitoring systems*. Retrieved April 25, 2011, from [www.rch.org.au/rchcp/index.cfm?doc\\_id=12860](http://www.rch.org.au/rchcp/index.cfm?doc_id=12860)
- Sadashivaiah, J., & McLure, H. (2009). 18-G tuohy needle can reduce the incidence of severe postdural puncture headache. *Anaesthesia*, *64*, 1371–1383.
- Sullivan, J., & Severance-Lossin, L. (2005). Intracranial bolt insertion (assist), monitoring, care, troubleshooting, and removal. In D. Wiegand & K. Carlson (Eds.), *AACN Procedure Manual for Critical Care* (5th ed.; pp. 730–7). St. Louis: Elsevier Saunders.
- Trautner, B. W., Clarridge, J. E., & Darouiche, R. O. (2002). Skin antiseptics kits containing alcohol and chlorhexidine gluconate or tincture of iodine are associated with low rates of blood culture contamination. *Infection Control and Hospital Epidemiology*, *23*(7), 397–401.
- Tunkel, A. R., Hartman, B. J., Kaplan, S. L., Kaufman, B. A., Roos, K. L., Scheld, W. M., et al. (2004). Practice guidelines for the management of bacterial meningitis. *Clinical Infectious Disease*, *39*, 1267–1284.
- Ugboma, S., Au-Truong, X., Kranzler, L. I., Rifai, S. H., Joseph, N. J., & Ramez-Salem, M. (2002). The breaking of an intrathecally placed epidural catheter during extraction. *Anesthesia and Analgesics*, *95*, 1087–1089.
- Zhong, J., Dujovny, M., Park, H. K., Perez, E., Perlin, A. R., & Diaz, F. G. (2003). Advances in ICP monitoring techniques. *Neurological Research*, *25*, 339–350.

# Appendix A

Sample checklists of supplies for EVD cart. The cart is similar in size to a traditional “code cart” and is available in case of emergent insertion. The checklist allows supply levels to be assessed every 24 hours.

## Checklist of New York Presbyterian Hospital—EVD Cart Checklist

<b>Drawer 1</b>									
Betadine soap	2								
Betadine paint	2								
Chloroprep sticks	10								
Disposable clippers	10								
Gauze sponges 4x4	1 box								
Sterile OR towels	2								
<b>Drawer 2</b>									
Small Tegaderm	1 box								
Large Tegaderm	1 box								
Hemostat	3								
Suture removal kits	3								
Sutures (3.0 nylon)	5								
Sutures (2.0 silks)	5								
12-ml syringes	10								
Clear transport bags	10								
Black specimen tubes	10								
<b>Drawer 3</b>									
NS bacteriostatic	10								
Aline kit	4								
Masks	10								
Gloves (7.5)	5								
Gloves (8)	5								
Drawer 4									
Sterile gowns	4								
Head covers	10								
Sterile drape split sheet	2								
Sterile drape large sheet	2								
<b>Drawer 5</b>									
EVD drainage system	3								
EVD catheter	5								
<b>Drawer 6</b>									
Cranial access kit	4								

Courtesy of Mary Presciutti

## Appendix B

The following table is an example of a policy and procedure for CSF sampling and flushing ventricular catheter (away from the patient). *Note:* Nurses are responsible for following their individual institution's policies and procedures. Some institutions restrict the number of personnel who obtain CSF samples or flush ventricular catheters.

### CSF sampling (ICU only)

1. Gather a 3 mL syringe, povidone-iodine swab, sterile 2x2 gauze, sterile gloves, and mask.	
2. Use strict aseptic technique to obtain sample.	
a. Clamp tubing 5–10 minutes before drawing sample.	a. This allows CSF to reaccumulate in ventricles.
b. Wear mask and sterile gloves.	
c. Scrub needleless sample port closest to patient's head with povidone-iodine. Wipe off excess povidone-iodine from port with 2x2 gauze.	c. Do not draw sample from stopcock to minimize opening the system. Use of the needleless port limits collection of CSF in port with stopcock.
d. Withdraw CSF slowly from port using a 3-ml syringe. Cap syringe and sample port with sterile airtight non-injectable cap.	d. CSF should flow freely into syringe. Do not aspirate if significant resistance encountered.
e. Label syringe with patient name. Send CSF for glucose, protein, cell count and gram stain and culture.	e. This specimen may be sent through the pneumatic tube system.

### Flushing ventricular catheter (ICU only )

1. Obtain order to flush catheter if catheter becomes obstructed and is not draining.	1. The catheter may be flushed once per episode of obstruction (maximum 3 times per shift) by an RN if ordered by physician. Subsequent flushes must be done by the physician if initial flush does not result in catheter patency. If patient's ICP is elevated with evidence of poor compliance (e.g., sustained elevation of ICP in response to stimulus), discuss reducing flush volume with physician or defer catheter flushing to physician.
2. Gather 3 ml syringe, sterile 2x2 gauze, povidone-iodine swab, sterile gloves, mask, sterile syringe and vial of preservative-free normal saline or prefilled 10-ml preservative-free sterile normal saline syringe.	
3. Scrub needleless sample port closest to patient's head with povidone-iodine. Wipe off excessive povidone-iodine using 2x2 gauze.	
4. Close clamp on catheter tubing above sample port.	4. Clamping tubing allows flush to move toward obstruction rather than toward collection chamber.
5. Using strict aseptic technique, draw up 1 ml preservative-free normal saline into syringe.	
6. Slowly flush catheter with 0.5–1 ml of preservative-free sterile normal saline. Do not attempt to aspirate obstruction. Notify physician if drainage not re-established.	
7. Record procedure, volume used to flush catheter, and results.	
8. If flushing to clear obstruction between sample port and collection chamber, turn stopcock between sample port and patient off to ventricular drain. Subtract volume of flush from hourly drainage total.	8. Turning stopcock off to drainage catheter is critical to preventing inadvertent flushing of excessive volume into ventricles.

*Courtesy of Pat Blissitt and Harborview Medical Center*